

AI**PennHIP**

(877) 727-6800

www.antechimagingervices.com

Owner's Copy

PennHIP Report

Referring Veterinarian: Dr Dwight Sinner
Email: sisqvet@gmail.com

Clinic Name: Siskiyou Veterinary Hospital
Clinic Address: 100 W. Stewart Ave.
Medford, OR 97501
Phone: (541) 773-1335
Fax: (541) 772-3654

Patient Information

Client: BENSON, CINDY
Patient Name: BB 2019 PINK SHOULDER
Reg. Name:
PennHIP Num: 134657
Species: Canine
Date of Birth: 08 May 2019
Sex: Female
Date of Study: 11 Sep 2019
Date of Report: 12 Sep 2019

Tattoo Num:
Patient ID: 21901 PINK SHOULDER
Registration Num: BCF6777
Microchip Num: XXXXXXXXXX
Breed: MAREMMA SHEEPDOG
Age: 18 weeks
Weight: 45 lbs/20.4 kgs
Date Submitted: 11 Sep 2019

Findings

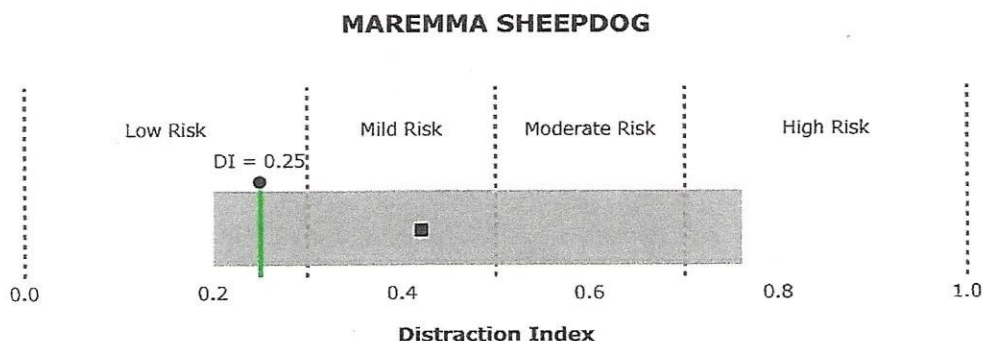
Distraction Index (DI): Right DI = 0.25, Left DI = 0.24.
Osteoarthritis (OA): No radiographic evidence of OA for either hip.
Cavitation/Other Findings: No cavitation present.

Interpretation

Distraction Index (DI): The laxity ranking is based on the hip with the greater laxity (larger DI). In this case the DI used is 0.25.

OA Risk Category: The DI is less than or equal to 0.30. This patient is at minimal risk for hip OA.

Distraction Index Chart:



BREED STATISTICS: This interpretation is based on a cross-section of 95 canine patients of the MAREMMA SHEEPDOG breed in the AIS PennHIP database. The gray strip represents the central 90% range of DIs (0.20 - 0.76) for the breed. The breed average DI is 0.42 (solid square). The patient DI is the solid circle (0.25).

SUMMARY: The degree of laxity (DI = 0.25) falls within the central 90% range of DIs for the breed. This amount of hip laxity places hip at a minimal risk to develop hip OA. No radiographic evidence of OA for either hip.