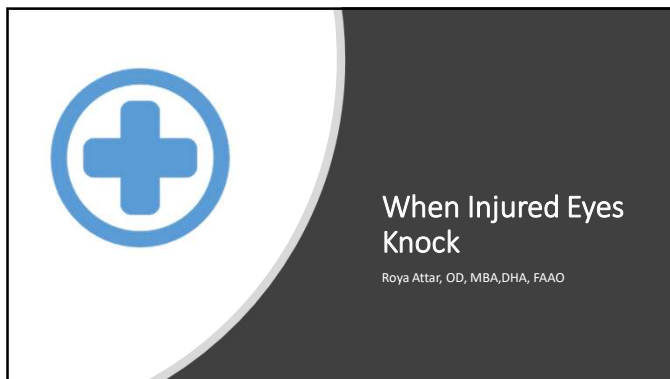



Speaker Disclosures

Roya Attar, OD, MBA, DHA, FAAO, FORS

- **Associate Professor & Director of Optometric Services at the University of Mississippi Medical Center Dept of Ophthalmology**
- **Speaker/ Advisory Board Member for**
 - Alcon Pharmaceuticals
 - Astellas Pharmaceuticals
 - Heidelberg Engineering
 - B & L
 - Tarnis Pharmaceuticals
 - Glaukos
 - Dompé
 - Teupoint Therapeutics
 - Optos
 - Sydexis
- **Contact information:**
 - roya.attar@umc.edu
 - [in](https://www.linkedin.com/in/roya_attar) @drroya_attar
 - Roya Attar

All relevant relationships have been mitigated

Content and Images Subject to Copyright

Course Objectives

- To discuss issues surrounding an optometric office availability and capabilities of managing ocular trauma cases
- To review the clinical findings of various ocular structures as it relates to a variety of injuries
- To review the proper management of each of the various findings

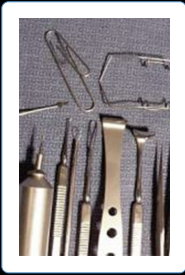
Introduction

- An estimated 2.4 million eye injuries occur in the U.S. annually. Nearly
- 35% of all eye injuries occur in people 18 to 45 years of age
- 40% of monocular blindness is related to trauma
 - The **leading cause** of monocular blindness
- 70-80% injured are male
- Average age 30y
 - Most common cause of visual loss in persons under age 25
- Using protective eyewear can prevent 90% of all eye injuries

Source: The scope of the problem, Prevent Blindness America

Introduction

- Importance of handling emergency and injury cases
 - Patients seeking care
 - Proper management will minimize or prevent further complications
- Handling phone call and office inquiries
 - Office protocol
 - Doctor's availability/liability, etc.
 - Training the office personnel
- Necessary Instrumentation

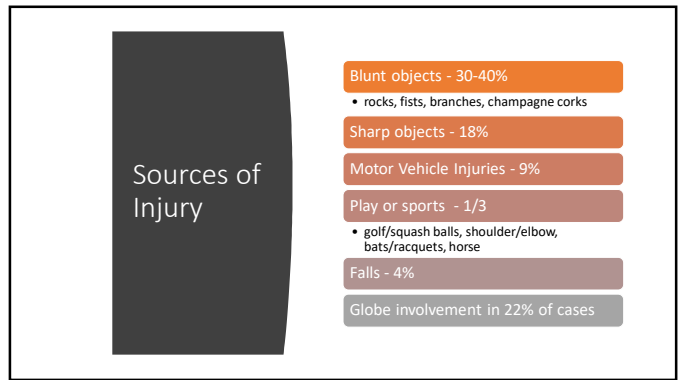
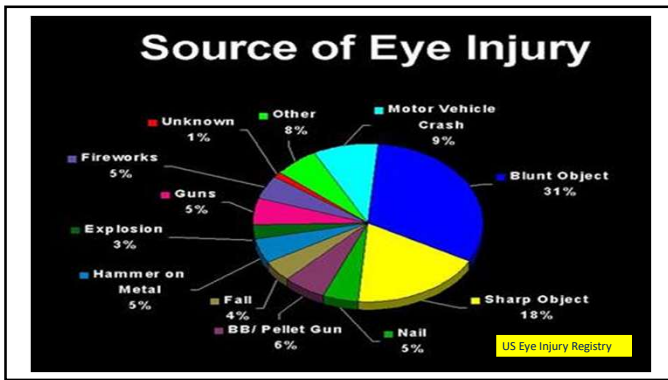
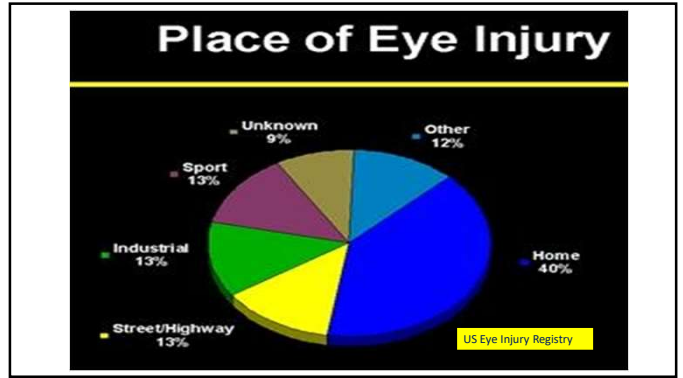
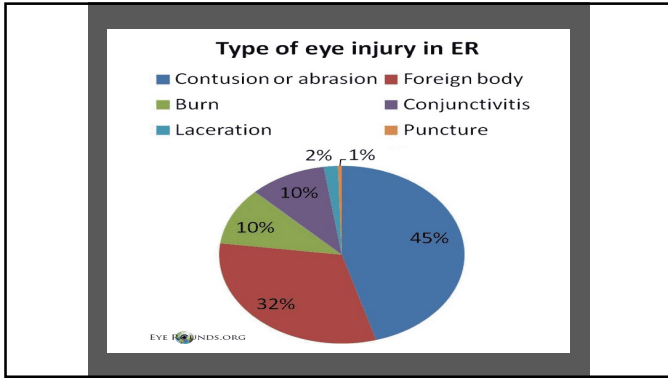


Epidemiology of Eye-Related Emergency Department Visits

From 2006 to 2011: 11,929,955 ED visits

- For ocular problems in the US were categorized as
 - Emergent (41.2%)
 - Nonemergent (44.3%)
 - Unable to determine (14.5%)
- Leading **diagnosis** in Emergent Category
 - Corneal abrasions (13.7%)
 - Foreign body in the external eye (7.5%)
 - Conjunctivitis (28.0%)
 - Subconjunctival hemorrhages (3.0%)
 - Styes (3.8%)

Source: Channa et. al, JAMA Ophthalmology, 2016 Mar;134(3):312-9

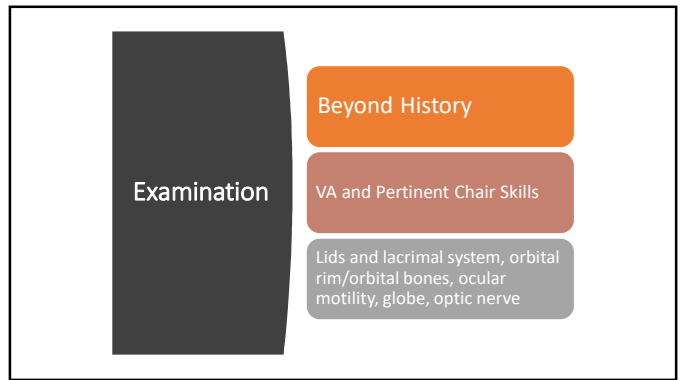
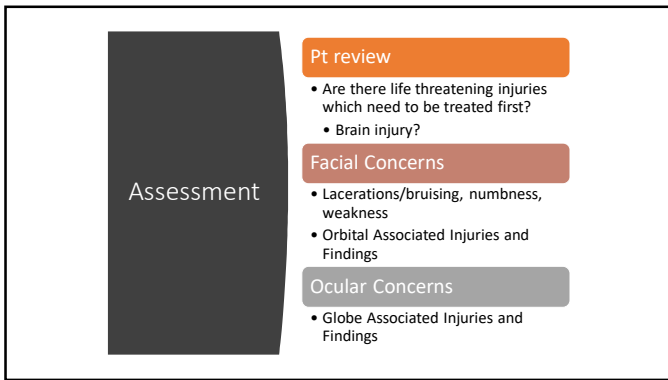
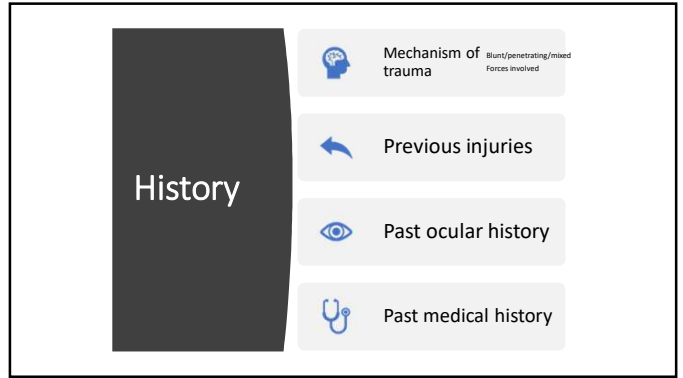
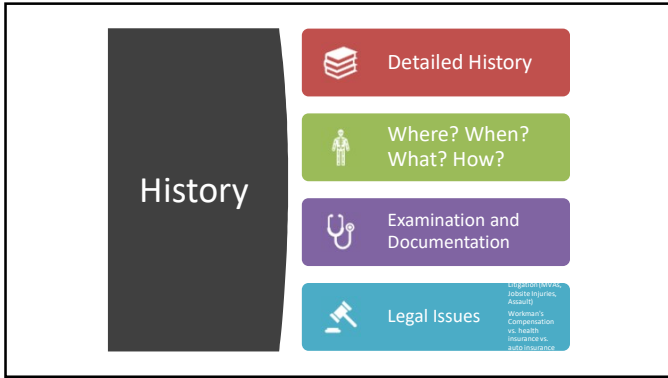

Ocular Trauma

- Assessment of Trauma
 - Nature of injury
 - Blunt (Penetrating or Lacerating)
 - Chemical
 - Location of injury
 - Peri-ocular
 - Anterior segment
 - Posterior segment

Criticality of Assessment and Management Period
Effecting the Outcome
Emergencies vs. Urgencies


- In **Emergencies** Minutes Matter
 - True Ocular Emergencies
 - Retinal artery occlusion (for visual outcome) and a Medically Urgent Condition
 - Chemical burns
- In **Urgencies** Hours Matters
 - Endophthalmitis
 - Penetrating Injuries
 - Orbital cellulitis (Medical Consequence)
 - Retinal Detachment



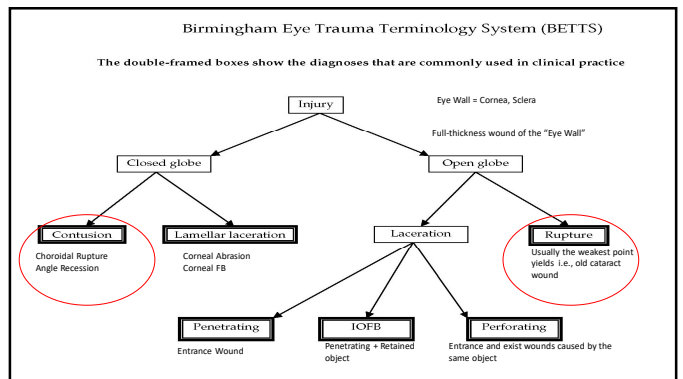
Blunt Trauma


Eye protected by bony orbit, orbital rim and the eyelids

<p>Anterior Segment</p> <ul style="list-style-type: none"> Orbit Eyelids Conjunctiva/Sclera Cornea A/C Iris Lens 	<p>Posterior Segment</p> <ul style="list-style-type: none"> Vitreous Retina/Optic Nerve Choroid
--	---



Bottle Rocket Injury





Orbital & Eyelid Emergencies

Orbital Trauma

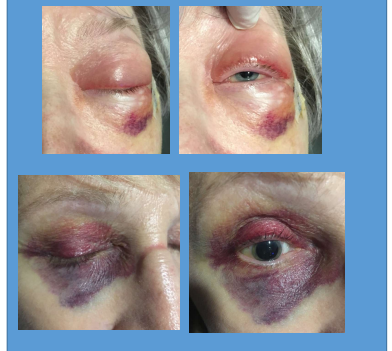
- Orbital hematoma
- Orbital fractures
- Orbital Foreign Body



Periorbital Hematoma



- Caused By Falling
- Common incident in patients, particularly nursing home population




Periorbital Hematoma

- If mild, treat with cool compresses
- If large amount of hemorrhage, especially behind the globe (Retrobulbar hemorrhage)
 - – may require emergency surgery to reduce intraocular pressure and protect corneal surface

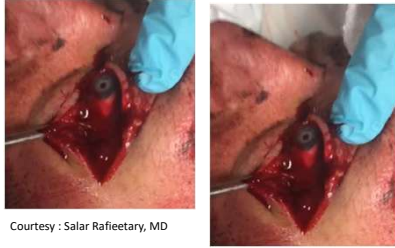Retrobulbar Hemorrhage

- Pain
- Decreased vision
- Proptosis
- RAPD
- Decreased EOM
- Elevated IOP
- May see on CT

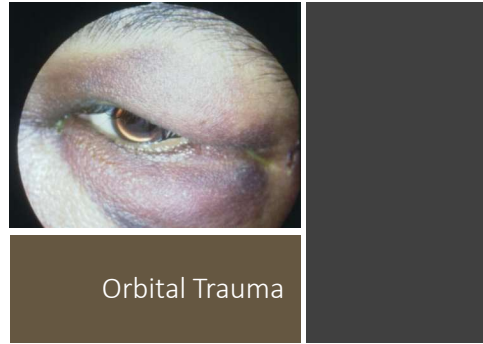


Courtesy: Salar Rafieetary, MD

**Orbital Compartment Syndrome
Lateral Canthotomy for Orbital Hemorrhage**

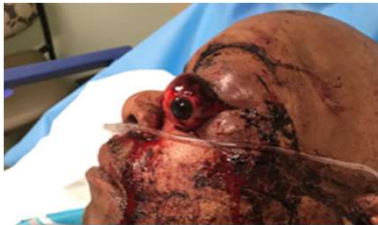

Courtesy : Salar Rafieetary, MD



Orbital Trauma

**Severe Traumatic Cases Managed at ERs and
Hospital Inpatient**



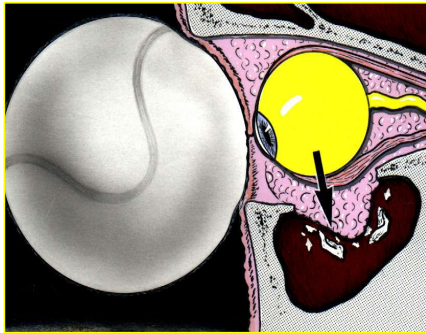
Courtesy: Salar Rafieetary, MD

Blunt
Ocular
Damage

The extent of ocular
damage depends
on:

- Size of the blunt object
- Hardness of the blunt object
- Velocity of the blunt object
- Force imparted directly to the eye

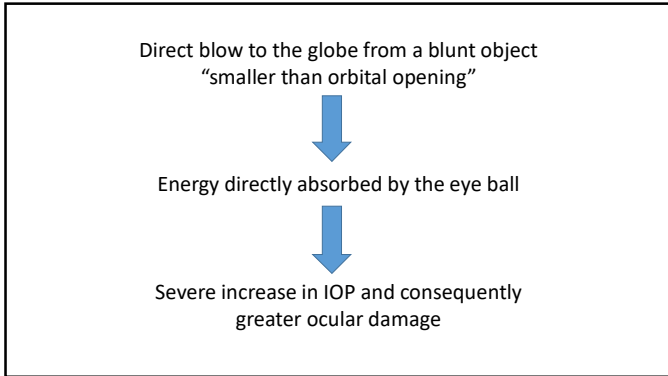
Pathogenesis of orbital floor blow-out fracture



Direct blow to the globe from a blunt object
"larger than the orbital opening"

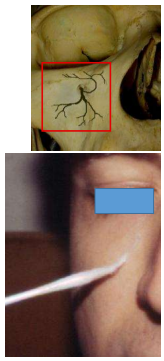
Energy absorbed by all of the orbital contents
leading to rise of intra-orbital pressure

Fractures of the thin bones of orbit
This "pressure-release valve" may prevent
serious ocular injury




Orbital Fractures

- Signs/Symptoms
 - Tenderness on palpation
 - Crepitation
 - Infraorbital nerve anesthesia or hyposthesia
 - Epistaxis (nose bleed)
 - EOM restriction/Diplopia (vertical)
 - Difficulty with jaw movement
 - Facial asymmetry
 - Enophthalmos



Signs of orbital floor blow-out fracture

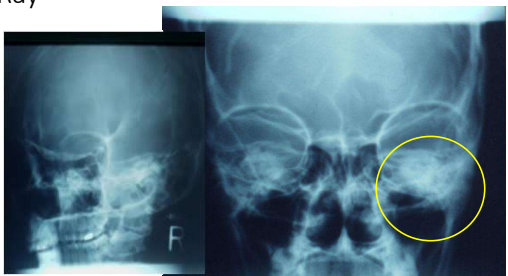


- Periorbital ecchymosis and edema
- Infraorbital nerve anesthesia
- Ophthalmoplegia - typically in up- and down-gaze (double diplopia)
- Enophthalmos - if severe

Imaging

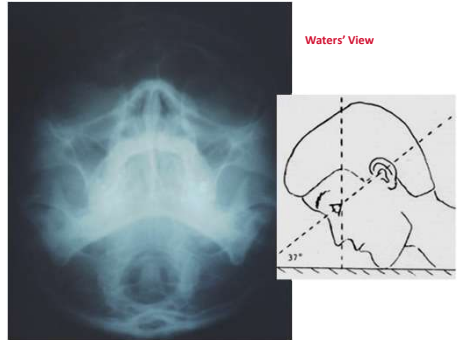
- X-ray
- CT
 - Axial and coronal
- MRI
 - No good - bone, metal FB
 - Subdural optic nerve haematoma

X-Ray



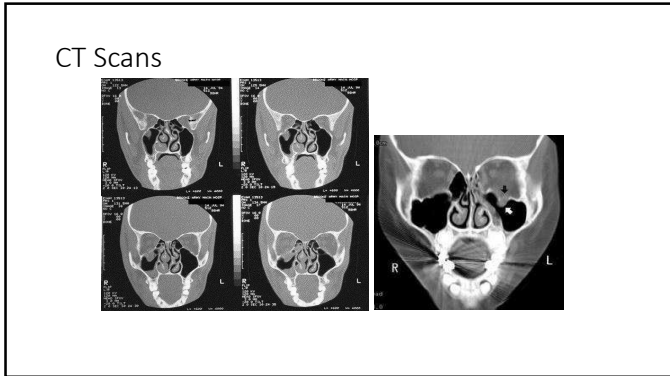
Lateral

Caldwell View (A-P)



Waters' View

37°



Treatment

- Surgery not required unless persistent diplopia or poor cosmesis
- Surgery is usually delayed for 7-14 days to allow for resolution of swelling
- Nasal decongestants, broad-spectrum oral antibiotics, ice packs
- Instruct patient not to blow nose (1-2 days)

Medial Wall Fracture

Signs

Periorbital subcutaneous emphysema

Ophthalmoplegia - adduction and abduction if medial rectus muscle is entrapped

Treatment

- Release of entrapped tissue
- Repair of bony defect

Eyelid-Super Glue

- Warm compress to loosen
- May need to trim lashes
- Gently rub to remove
- Remove glue from Cornea
- Treat Corneal Abrasion if present

by Daniel Miller, MD Exclusive to EyeWorld

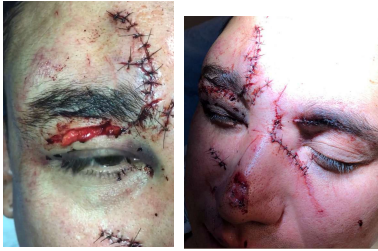One week after routine cataract surgery, a hostile patient called our office in severe pain. "Those eyedrops are killing me!" he said. I instructed him to come to our office right away and to bring all his medications with him. He had accidentally switched his Pred Forte (prednisolone acetate, Allergan) with Typewrite White-Out and, not surprisingly, had obvious irritation on slitlamp examination. Kindness, reassurance, and genuine Pred Forte helped his post-operative course back to a normal healing period. 🙏

Eyelid Lacerations

Courtesy: Salar Rafieetary, MD

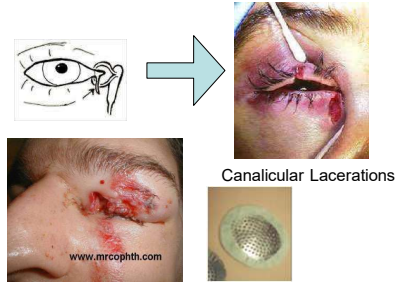
Full-thickness Lid Laceration
Etiologies: Animal Bites, MVA, Sports Injuries (fishing hooks), Assault

Combined Eyelid and Facial Lacerations



Courtesy: Salar Rafieetary, MD

Eyelid Laceration Assessment



Canalicular Lacerations

www.mrcophth.com



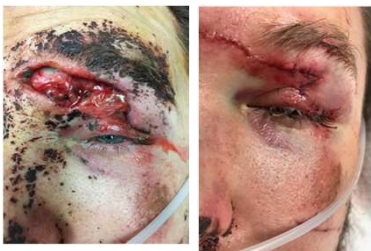Protection during Transfer

Eyelid Lacerations

Should always be concerned about underlying open globe

- Refer to oculoplastics for
 - Full-thickness laceration
 - Laceration involving medial 1/3 of lid
 - Deep lacerations with or without fat prolapse
 - Lacerations with significant tissue loss

Laceration Repaired



Courtesy: Salar Rafieetary, MD

Complications Secondary to Eyelid Lacerations

Lid margin notching

Lagophthalmos
• Due to scarring or tissue loss or septum into wound

Hypertrophic scars

Infection


Tearing
• Canalicular damage, lid malposition, pump failure

Traumatic ptosis
• Myogenic or neurogenic

Anterior Segment Trauma

Chemical Burns

- A vision-threatening emergency
- Immediate irrigation essential



Chemical Burns

- Acid vs. alkali**
 - Alkali more severe than acid burns
- Self-Induced**
- Treatment**
 - Immediate copious irrigation
 - Severe cases refer to appropriate ER
 - Do not use chemical antidotes
 - Monitor pH



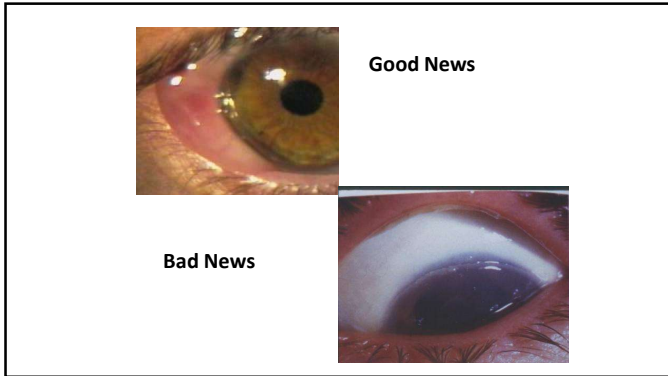
Irrigate immediately before anything else

Alkaline (bases)

- Fertilizers
- Cleaning products (ammonia)
- Drain cleaners (lye)
- Oven cleaners
- Bleach (sodium hydroxide)
- Fireworks (magnesium hydroxide)
- Cement (lime)
- High pH
- Especially damaging – will denature proteins and lyse cell membranes which enhances penetration

Acids

- Battery acid (sulfuric acid)
- Glass polish/etching (hydrofluoric acid)
- Vinegar
- Nail polish remover (acetic acid)
- Low pH
- Depth of penetration usually less due to precipitation of proteins



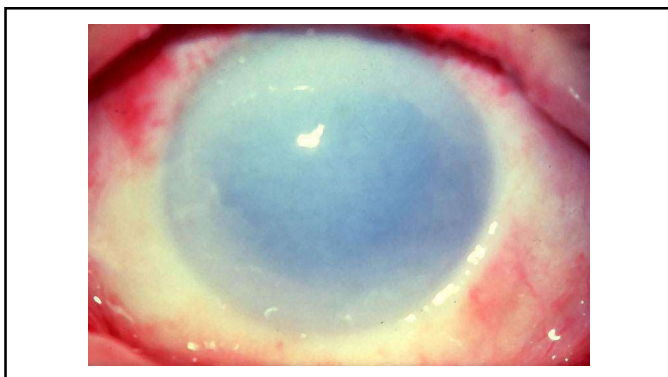
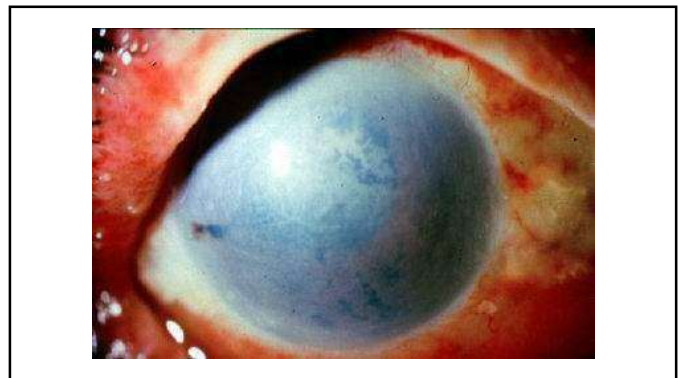
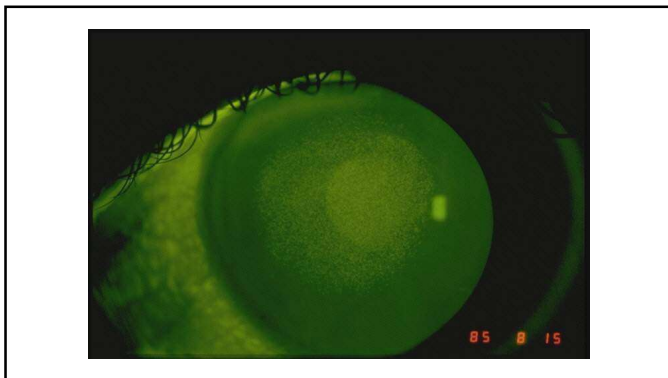
Grading of Severity of Chemical Injuries

- Grade I (excellent prognosis)**
 - Clear cornea
 - Limbal ischaemia - nil
- Grade II (good prognosis)**
 - Cornea hazy but visible iris details
 - Limbal ischaemia <1/3
- Grade III (guarded prognosis)**
 - Hazy cornea with no iris details
 - Limbal ischaemia 1/3 to 1/2
- Grade IV (very poor prognosis)**
 - Opaque cornea
 - Limbal ischaemia >1/2

Grade II

Grade III

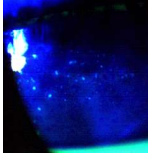
Grade IV



Chemical Burns

Treatment

- Immediate copious irrigation
 - Lid speculum may be helpful
- Severe cases refer to appropriate ER
- Do not use chemical antidotes
- Monitor pH
- Corneal defect should be followed up daily until healed




Burns

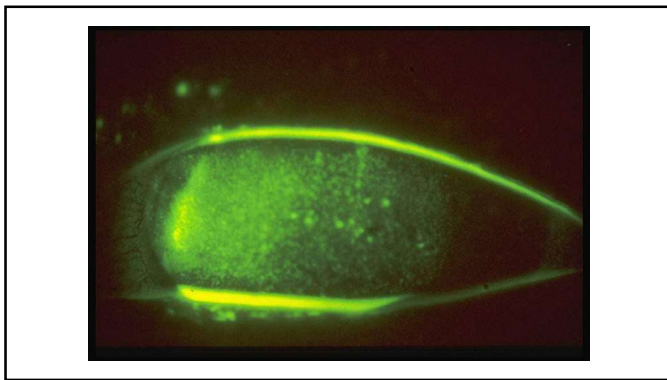
- Radiation
 - U.V.
- Thermal

Welding top cause of consumer product-related eye injuries

Ultraviolet Burn


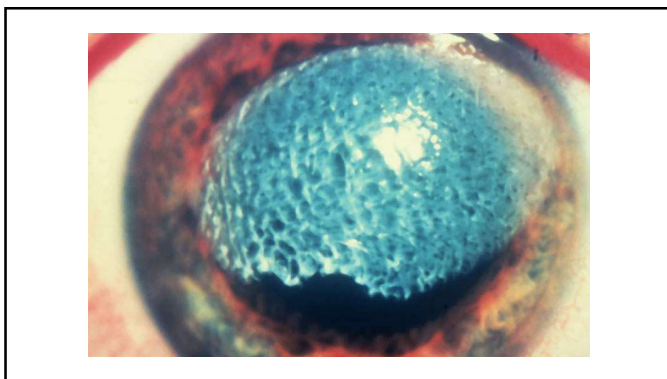


- Welding or sun lamps without eye protection
- Produces small, diffuse epithelial defects which stain with fluorescein
- Becomes severely painful several hours after exposure
- Treat with Cyclogyl, antibiotic ointment, and pressure patching

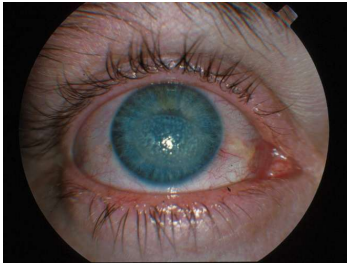


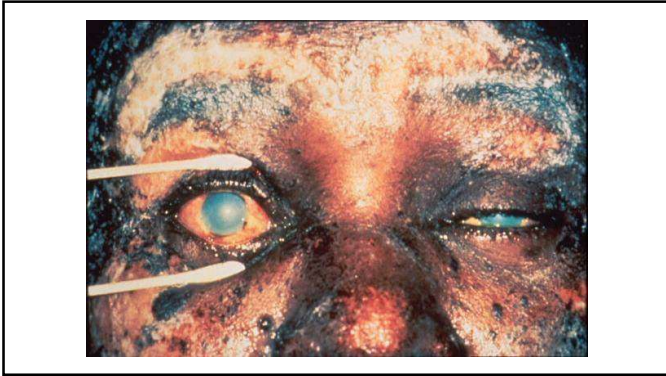Thermal Burn

- Most common – cigarettes and curling iron
- Usually superficial burns
- Treat like chemical burn except no irrigation needed
- May need debridement of burned tissue

Thermal Corneal Burn






Foreign Bodies

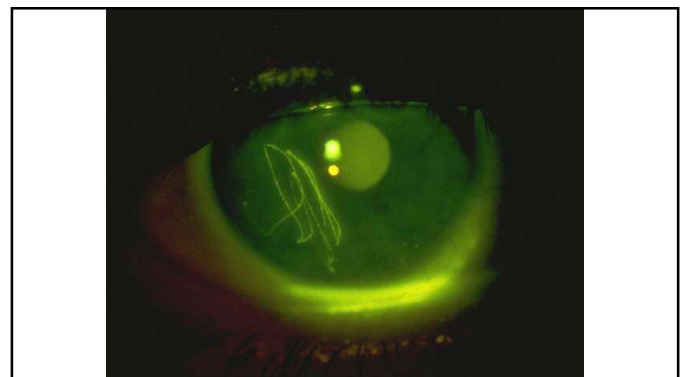
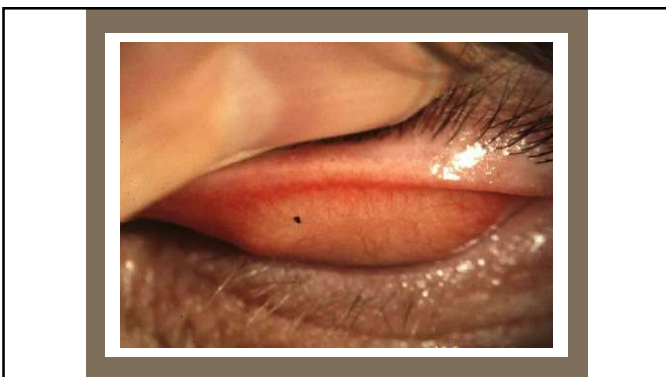- Superficial and Corneal FB most common injury seen in optometric practice
 - Superficial (Eyelid, Conj. Cornea)
 - Penetrating (retained) or Perforating

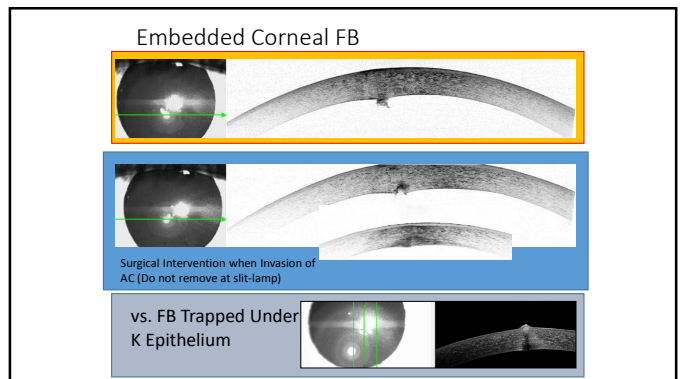
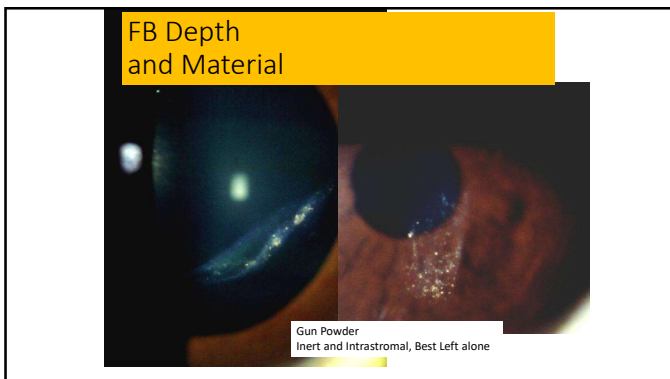
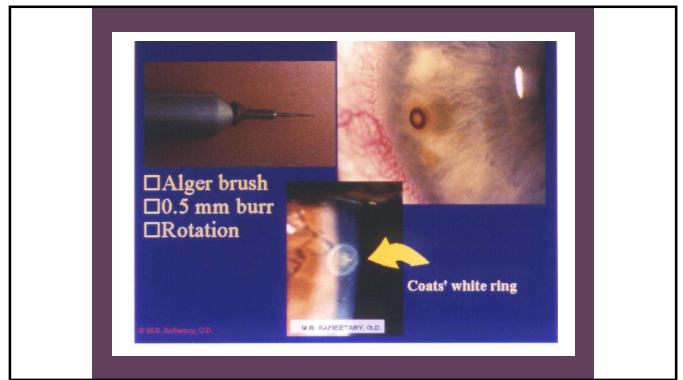
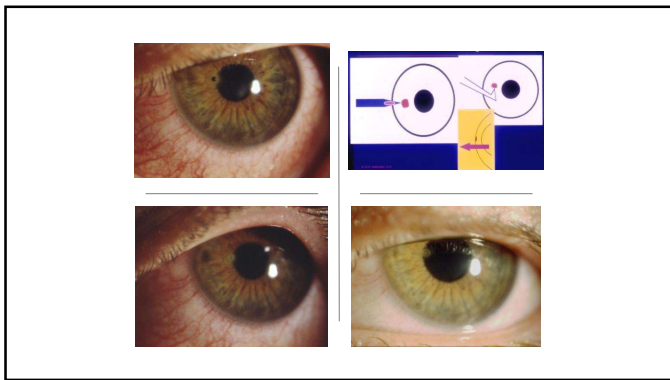
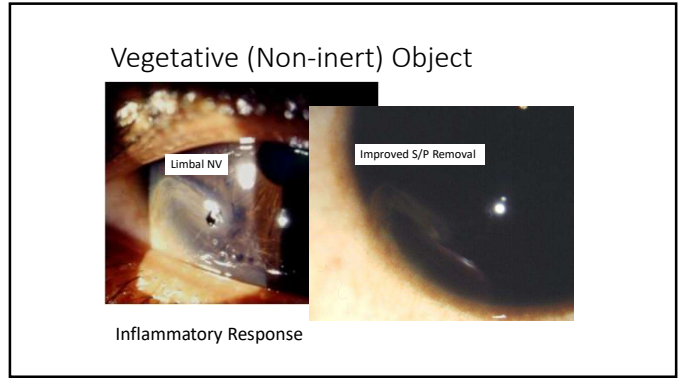
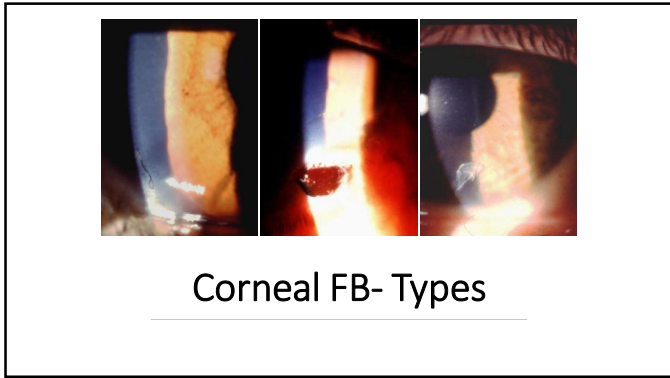


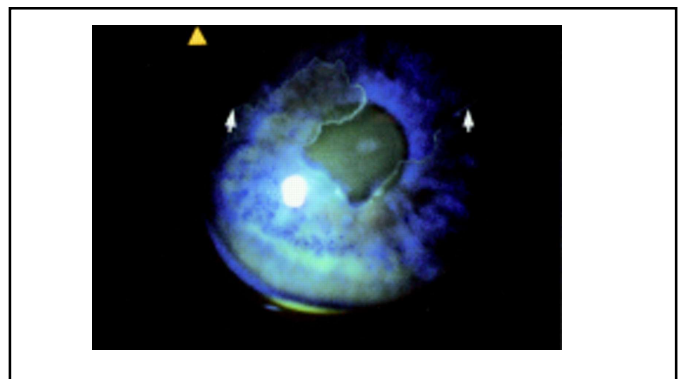
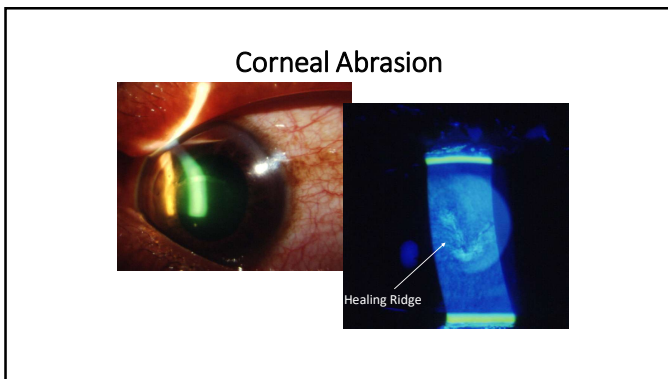
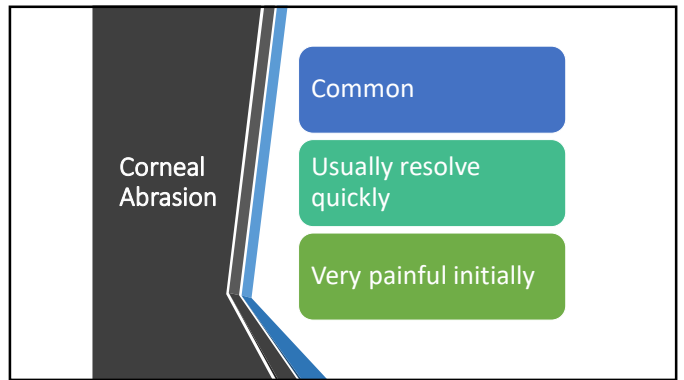
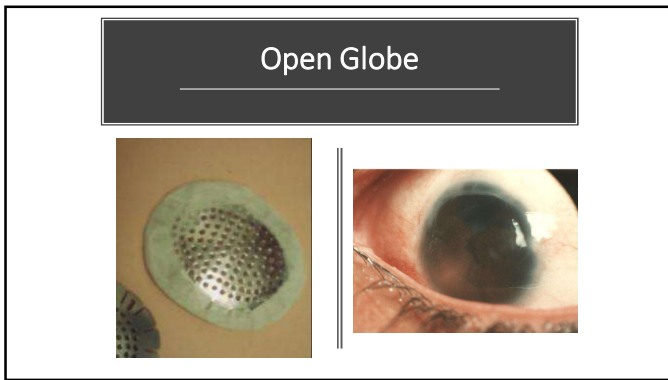
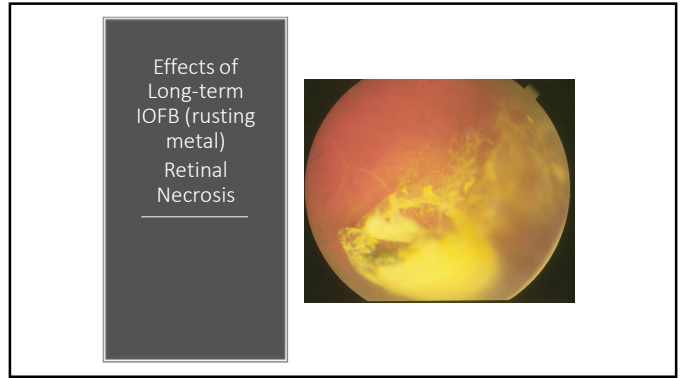
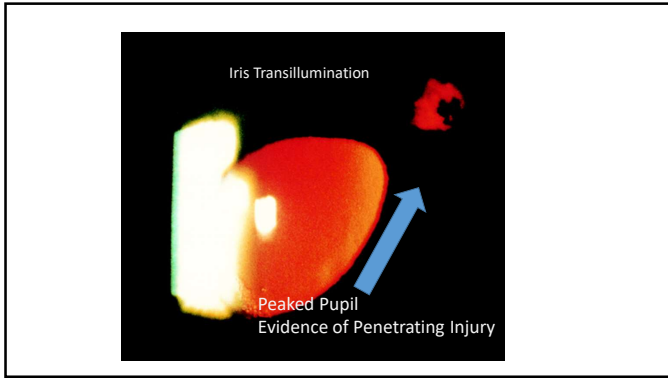
Superficial Foreign Body

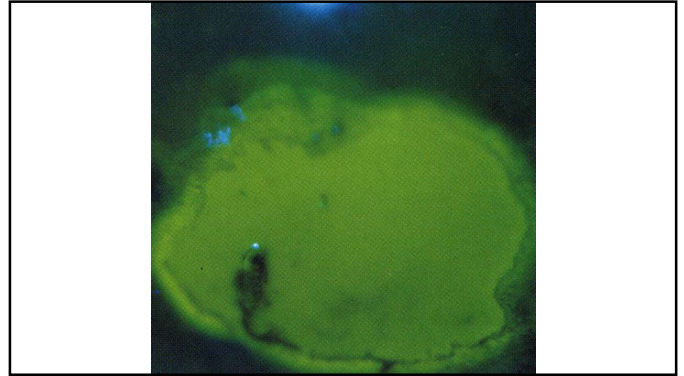
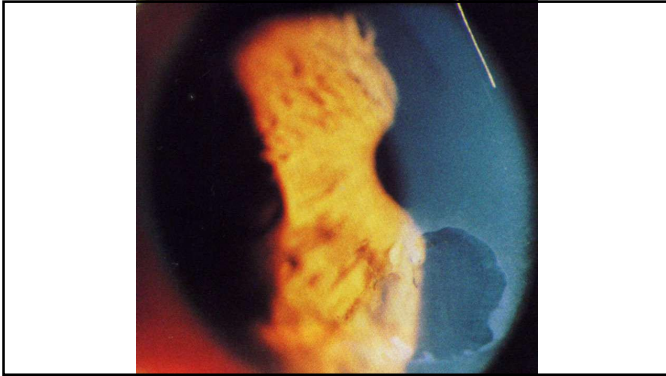
- Multiple linear epithelial defects suggests foreign body beneath the eyelid
- Be sure to flip upper eyelid with cotton-tip
- Can be removed if superficial with moist cotton-tip
- If embedded -- can be removed with cotton-tip or 25-gauge needle

Evert the Eyelids









Corneal Abrasions

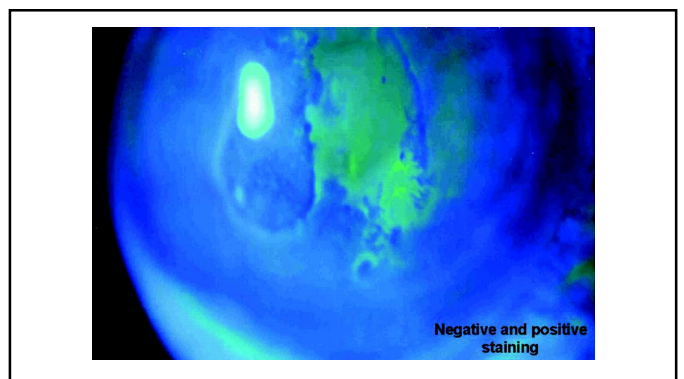
- Non-CTL Wearer: Antibiotic ointment/drop (e.g. Emycin/polytrim)**
 - Cycloplegic (cyclogyl bid)
 - May consider bandage CL, amniotic membrane
- CTL Wearer (Requires anti-pseudomonal coverage)**
 - Cycloplegic
 - DO NOT PATCH
 - No contact lens wear

Corneal Abrasions

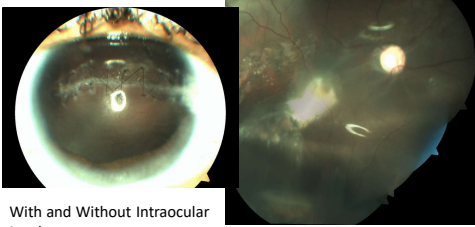
- Follow-up**
 - Large/central abrasion – Daily
 - Peripheral/small abrasion – 2-3d
 - CTL wearer—daily (once healed, no CTL wear for 1 week)

Recurrent Epithelial Erosion

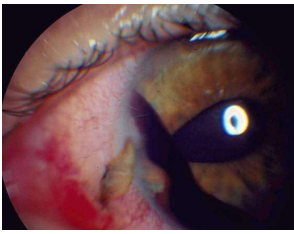
- History gives clue
- Often triggered by minor trauma
- Treatment**
 - Lubricants
 - Bandage contact lens
 - Amniotic membrane
 - Epithelial debridement
 - Tetracyclines
 - Laser Phototherapeutic Keratectomy (PTK)
 - Anterior Stromal Puncture



Corneal Laceration



With and Without Intraocular Involvement



- Irregular Pupil
- Due to iris prolapse through laceration

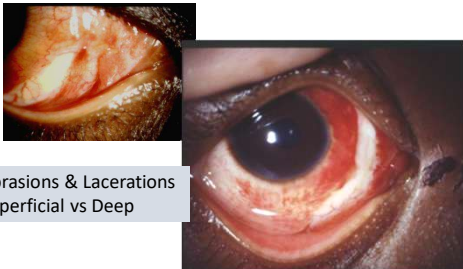
Corneal Laceration

Subconjunctival Hemorrhage

- Very common after blunt trauma
- Superficial blood vessels broken
- May occur spontaneously (Coumadin, aspirin, valsalva)
- Usually self-limited
- Treat with artificial tears and reassurance
- May be suggestive of ruptured globe




Conjunctival Injuries



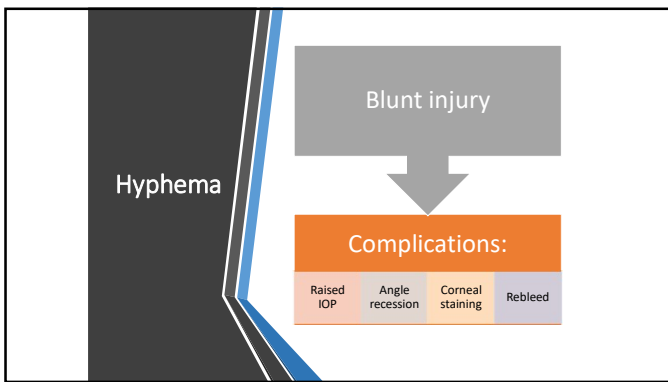
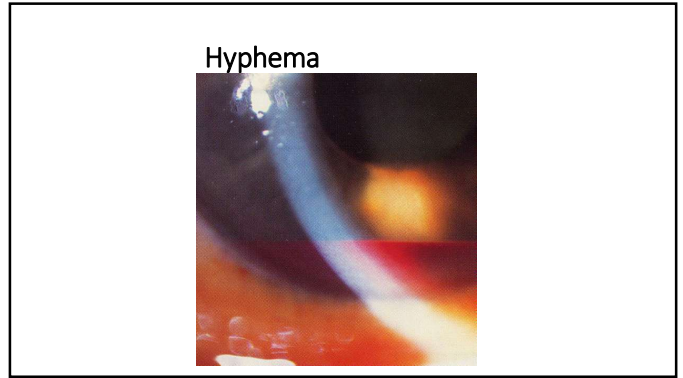
Abrasions & Lacerations
Superficial vs Deep

Bloody Chemosis



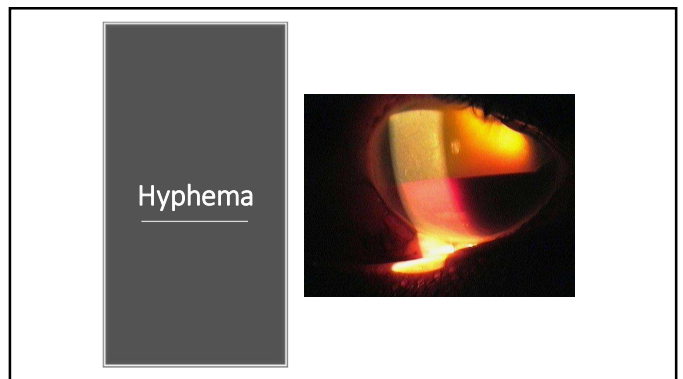
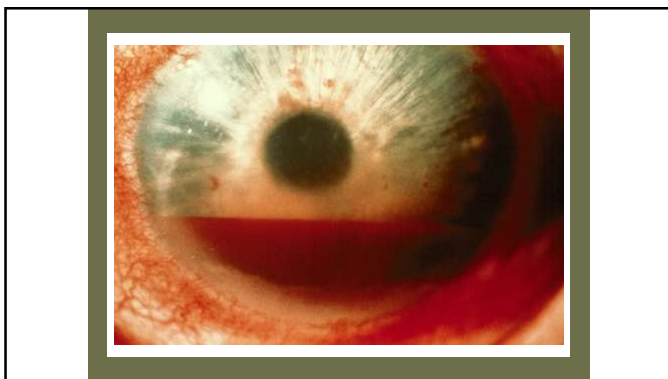Hyphema

- Blood in the anterior chamber
- Can be diffuse or layered
- Source of bleeding is the iris or ciliary body




Hyphema

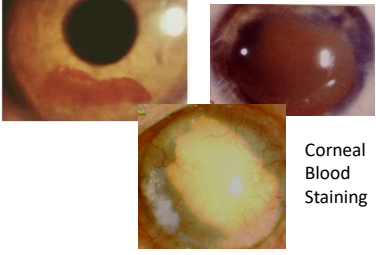
- Management
 - Hospitalize/bed-rest (head elevated at 30-45 degrees)
 - Protective shield
 - Cycloplegic-mydriatic, topical steroids
 - IOP monitor & control
 - Mild analgesics (avoid aspirin)
 - Rule out sickle cell
 - Surgical aspiration



Presentation of Rebreeding

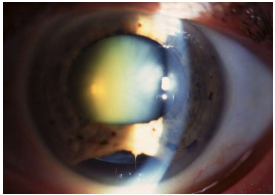


Hyphema, Chronic or Recurrent

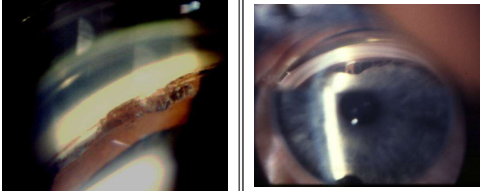


Corneal Blood Staining

Iris Dialysis




Angle recession



Traumatic Iritis

- Ranges from Mild to Severe
- Usually other injuries as well
- Treat as for non-traumatic Iritis but may not require long taper and will not require systemic work-up



Iritis

Post Traumatic Endophthalmitis

- 7% of cases
- Skin flora most likely cause
 - S aureus
- Consider Bacillus cereus if any soil
 - 8-25%
- Prophylactic antibiotics
 - Consider intravitreal if heavily contaminated
 - IV for 3-5d post-op
 - Topical also

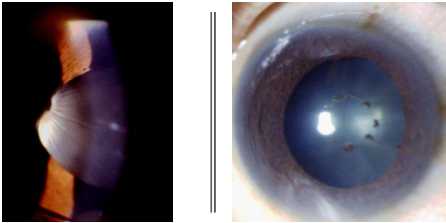
Endophthalmitis



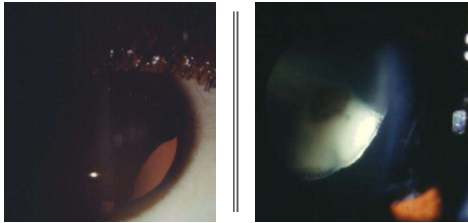
Sympathetic Ophthalmia

- <0.5% of penetrating injury
- Bilateral granulomatous uveitis
- AC inflammation, multiple yellow spots in peripheral fundus
- Complications
 - Cataract, glaucoma, optic atrophy, exudative detachments, subretinal fibrosis
- 80% within 3 months, 90% within 1 year
- Systemic immunosuppression
- Mostly good prognosis >6/18
- However, enucleate only if no visual potential

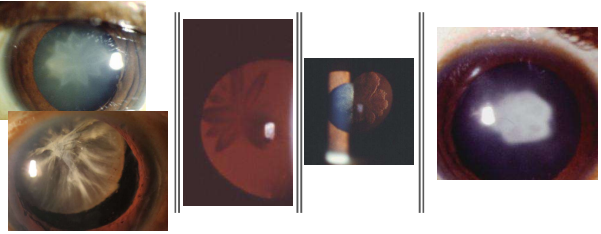
Lens-Capsular Findings

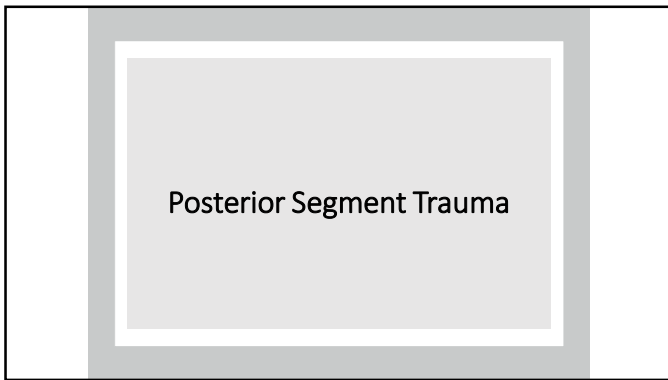
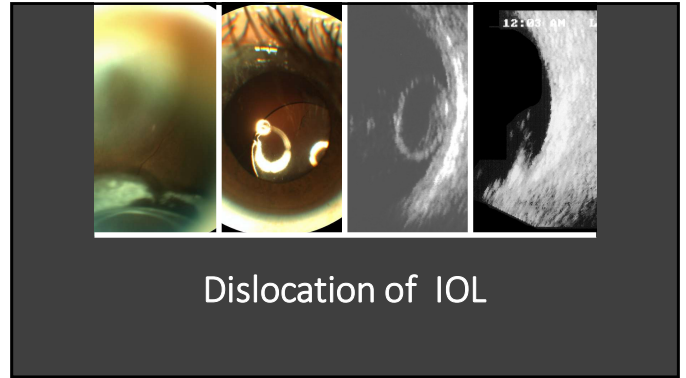
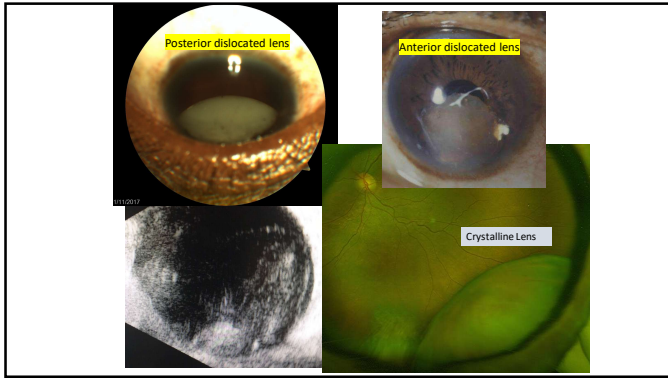


Zonular Dehiscence



Traumatic Cataract





Intraorbital/Intraocular Foreign Body

- High-speed projectile foreign body to eye or orbit
- Clinical Scenarios:
 - Weedeating or mowing
 - Grinding metal
 - Hammering or pounding metal
 - Motor vehicle accident

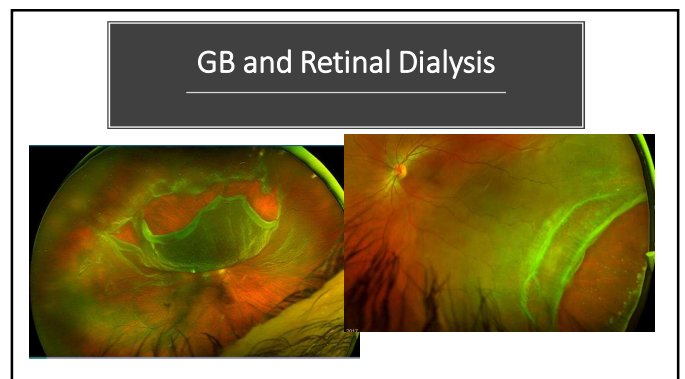
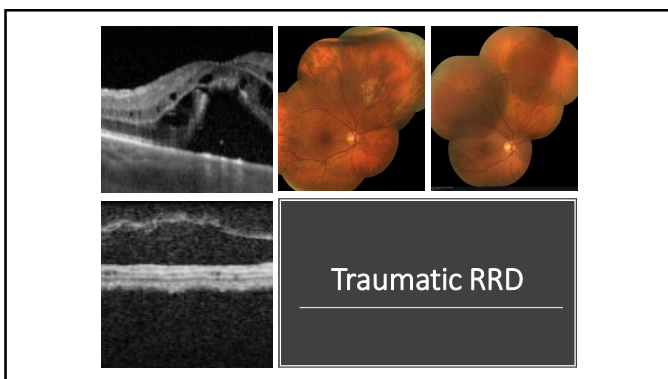
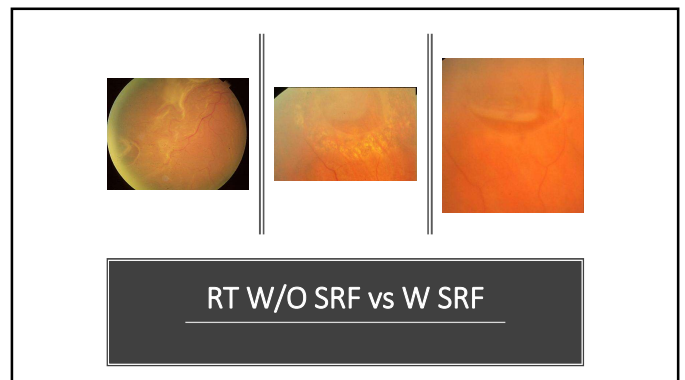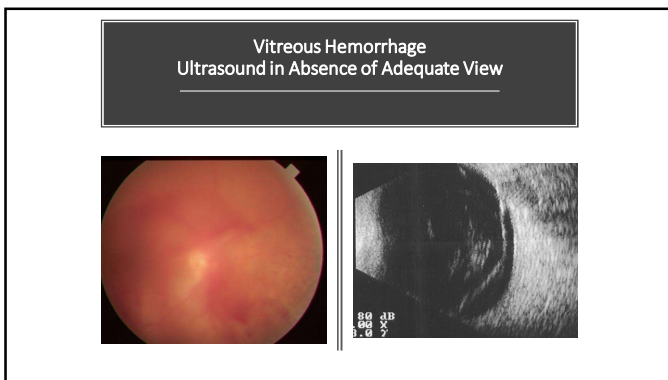
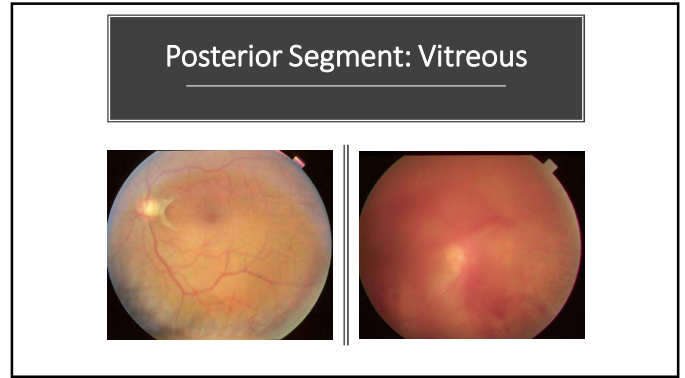
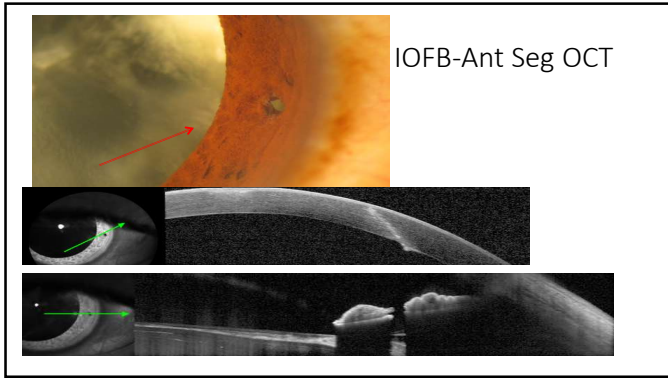
Intraorbital/Intraocular Foreign Body

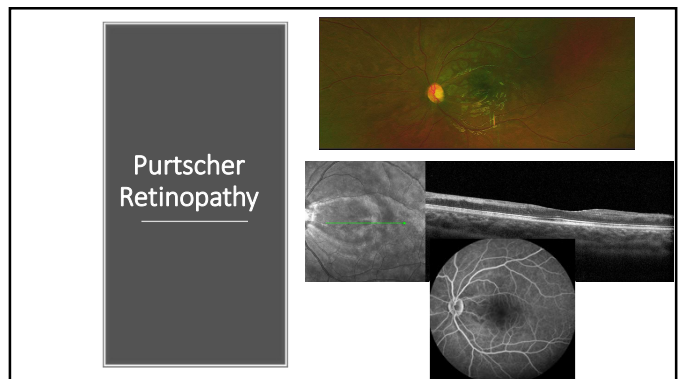
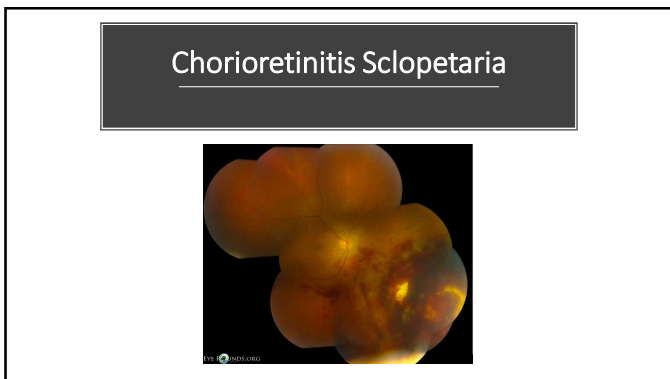
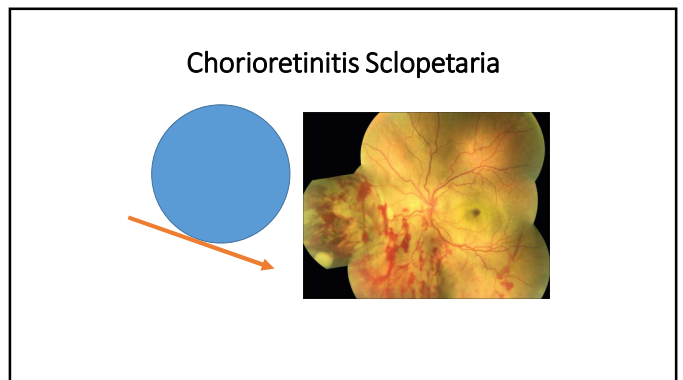
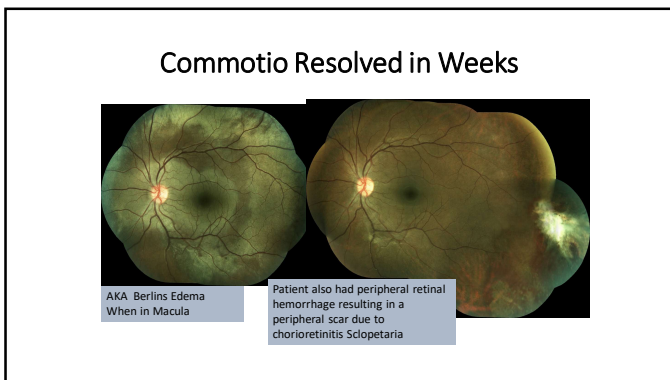
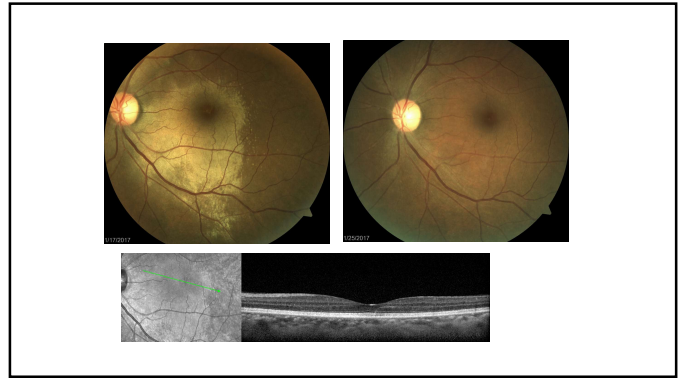
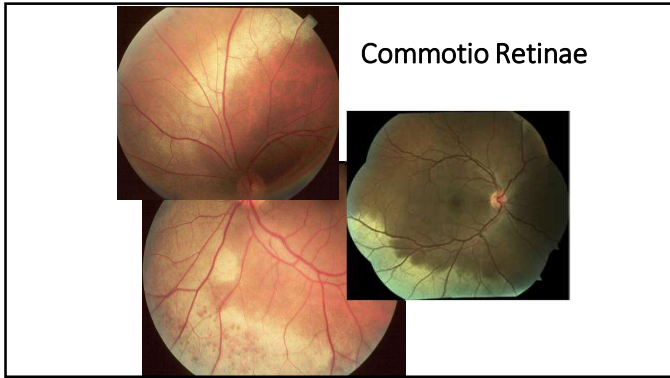
- Need to rule out injury to globe or intraocular FB -- requires surgery
- CT scan orbits (1mm cuts, Axial & Coronal)

Radiology for FB

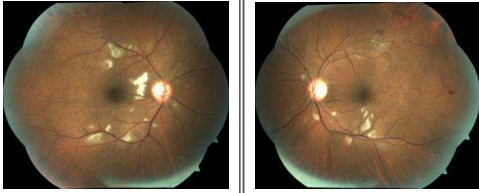
NO MRI

Magnetic Material

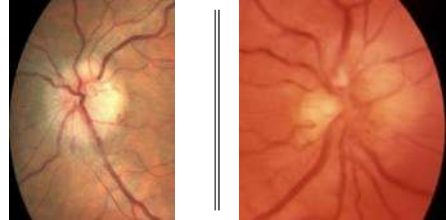




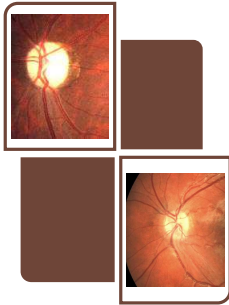
Purtscher Retinopathy



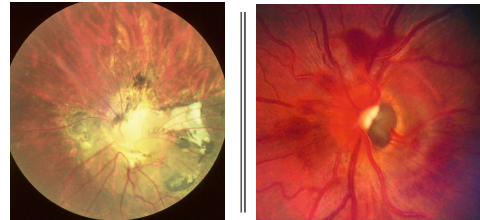
Traumatic Optic Neuropathy



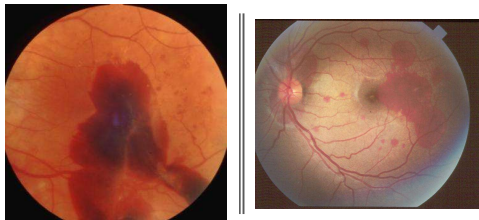
Traumatic Optic Neuropathy



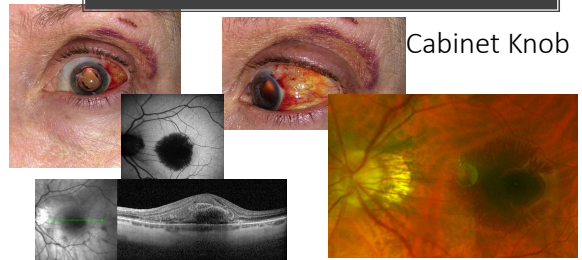
Optic Nerve Avulsion

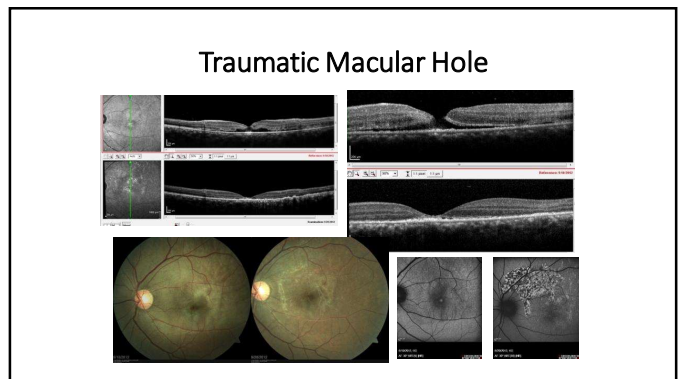
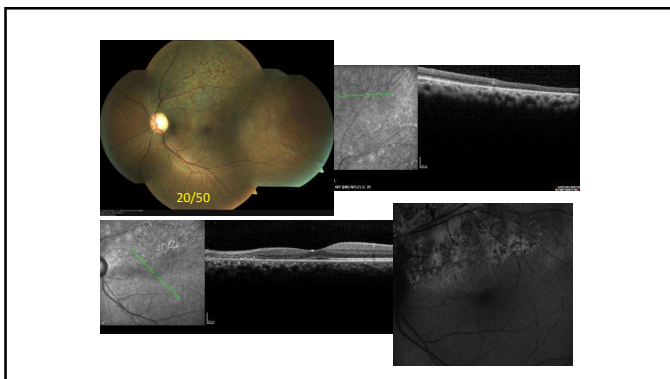
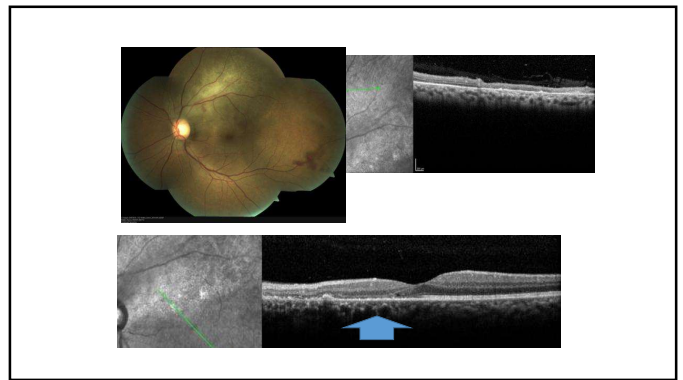
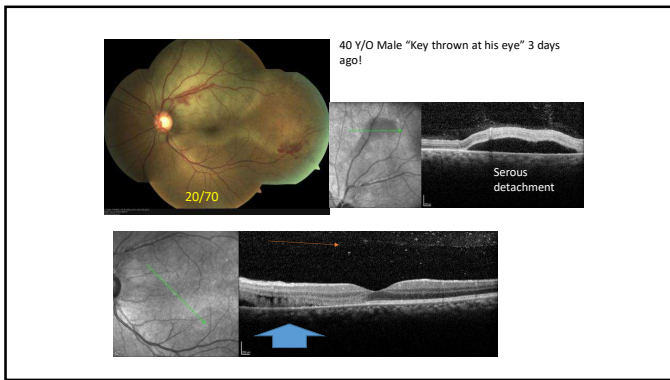
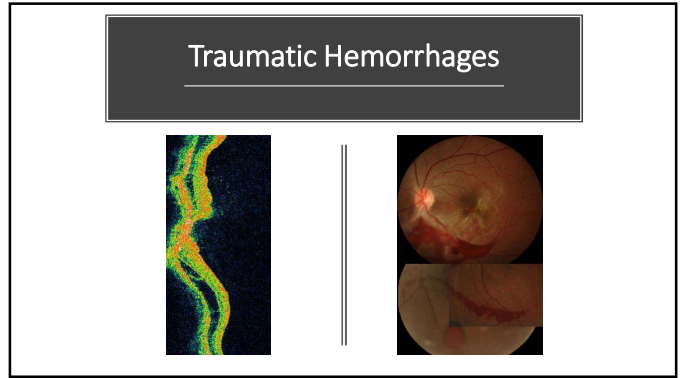
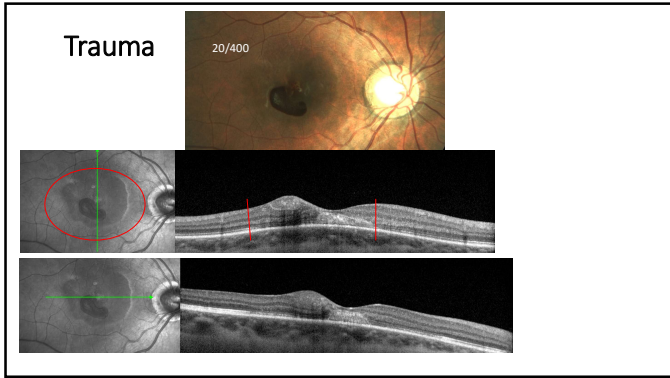


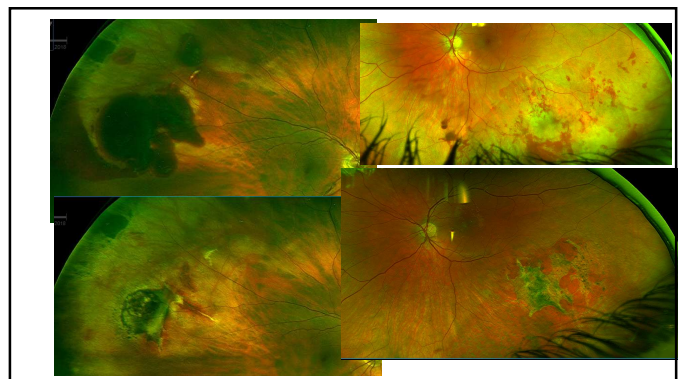
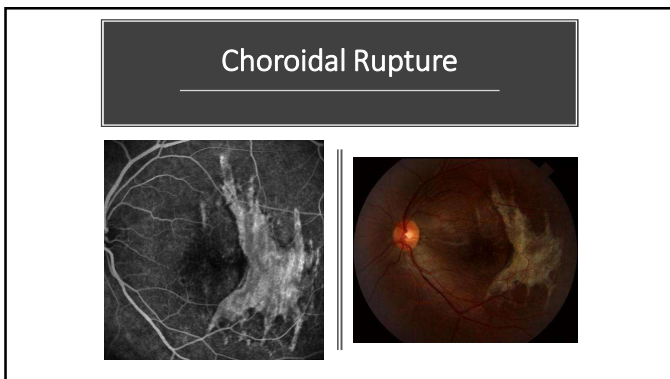
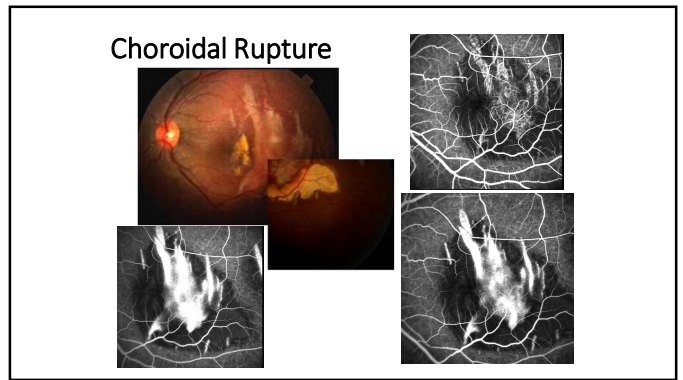
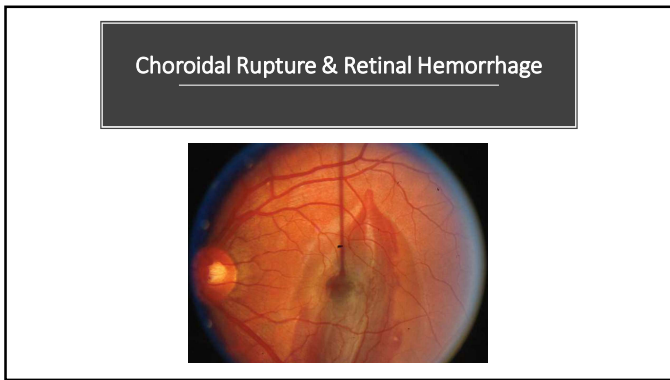
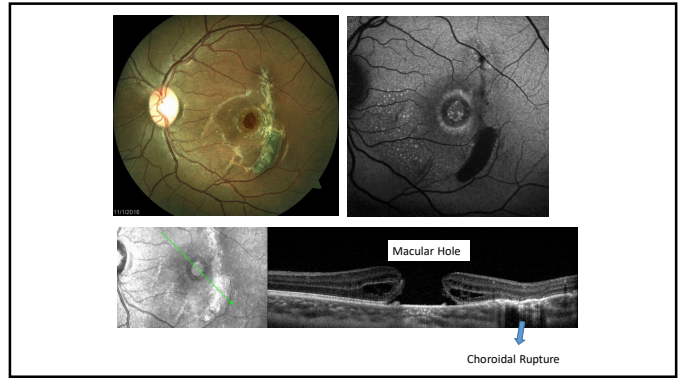
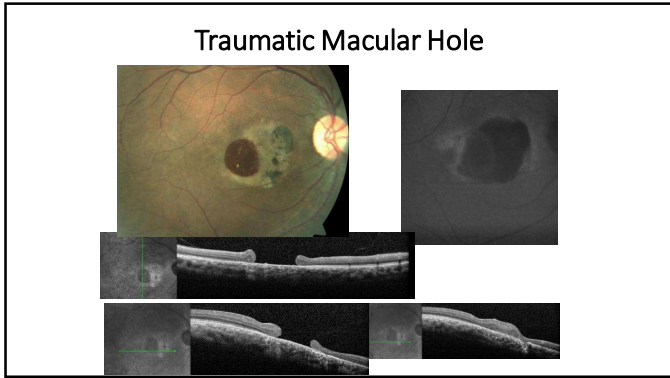
Traumatic Hemorrhages



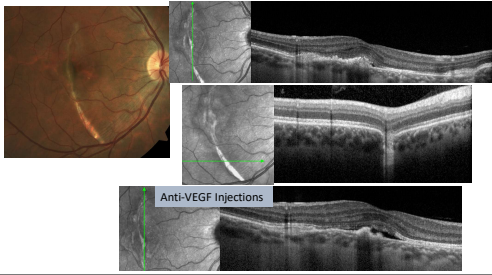Traumatic Hemorrhages



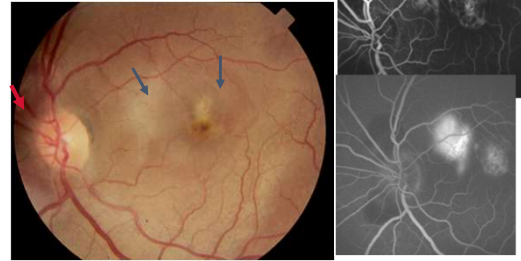




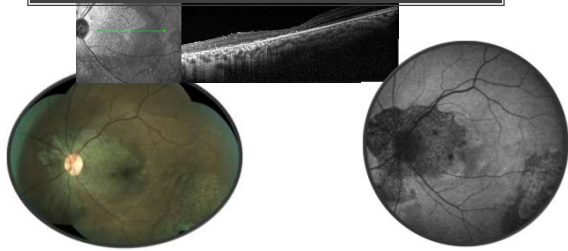
Choroidal Rupture (Secondary CNV)



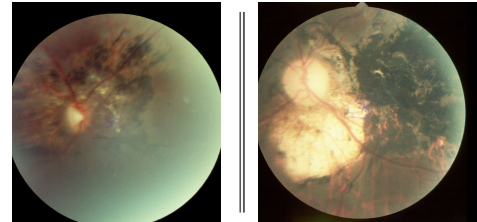
CNV



Traumatic Chorioretinal Scar



Traumatic Chorioretinal Scar

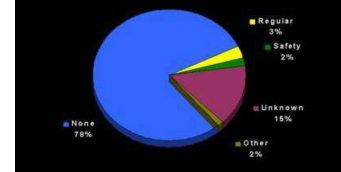


Eye Injuries

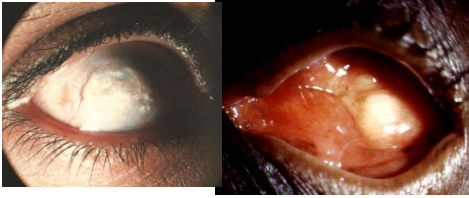
PREVENTION

Prevention

Eye Protection



End-Stage Disease!



Don't Let This Happen!



References

- Bagheri, Nika, et al., editors. *The Wills Eye Manual*. 7th ed., Lippincott Williams and Wilkins, 2016.
- Channa, Roomasa, et al. "Epidemiology of eye-related emergency department visits." *JAMA ophthalmology* 134.3 (2016): 312-319.
- EyeFound.org
- Gardin, Margot A., Bella J. Wolf, and Peter A. Kahn. "Nationwide emergency medical services guidelines for care of ocular emergencies." *Ophthalmology* 129.11 (2022): 1532-1533.
- Kaiser Peter K et al. *The Massachusetts Eye and Ear Infirmary Illustrated Manual of Ophthalmology*. Fourth edition Fourth ed. Saunders 2014.
- Prevent Blindness
- Salmon John F. *Kanski's Synopsis of Clinical Ophthalmology*. Fourth edition Fourth ed. Elsevier 2023.
- US Eye Injury Registry