

Effect of Low Level Laser Therapy on Brain Activity Assessed by QEEG and QEEGt in Normal Subjects

C Machado, Y Machado, M Chinchilla, S Shanks, H Foyaca-Sibat

Citation

C Machado, Y Machado, M Chinchilla, S Shanks, H Foyaca-Sibat. *Effect of Low Level Laser Therapy on Brain Activity Assessed by QEEG and QEEGt in Normal Subjects*. The Internet Journal of Neurology. 2018 Volume 20 Number 1.

DOI: [10.5580/IJN.52988](https://doi.org/10.5580/IJN.52988)

Abstract

Objectives: The use low-level laser therapy (LLLT) is steadily increasing in diverse areas of medicine including wound healing, relief from pain and inflammation, and treating neurodegenerative diseases. LLLT also appears to be beneficial for treating traumatic brain injury, depression, and cognitive disorders. The objective of this pilot study was to assess the effects of LLLT on brain activity in healthy volunteers.

Materials and Methods: Healthy male (n=5) and female (n=5) subjects, 22 to 28 years old were enrolled. A 20-minute electroencephalogram (EEG) was obtained before and after exposure to LLLT. EEGs were recorded using 19 monopolar derivations of the International 10-20 System with linked earlobes as reference. Using a hand-held probe, the entire skull of each subject was exposed to red 635 nm laser light for 10 minutes. EEG data were assessed using quantitative EEG (QEEG) and tomographic quantitative EEG (QEEGt) methods.

Results: Comparing EEG records before and after the application of LLLT revealed significant activation in several areas of the brain. Brain maps for alpha and gamma absolute powers demonstrated clear increments in nine subjects. A decrement in alpha and gamma absolute powers after LLLT stimulation only occurred in one subject. There were no reported adverse events.

Conclusion: Exposing the brain to 635 nm laser light for 10 minutes resulted in significant activation of several areas of the brain. Further research should be done with a larger sample to create a larger body of normative data for comparing the effects of LLLT for treating various neurological diseases.

Conflict of Interest Statement: Mr. Shanks is an employee of the company which manufactures the low-level laser device used in this study. The remaining authors have stated explicitly that there are no conflicts of interest in connection with this article.

INTRODUCTION

In 1967, the Hungarian Endre Mester first proposed the use of low-power laser to increase hair growth and stimulate wound healing in mice^{1,2} and shortly afterwards, he began using lasers to treat patients with non-healing skin ulcers.³ Since that time, the use low-level laser therapy (LLLT), also known as nonthermal laser and photobiomodulation, its use has steadily increased in diverse areas of medicine such as wound healing, relief from pain and inflammation and treating neurodegenerative diseases.^{4,5}

Experimental transcranial photobiomodulation using LLLT has been reported to stimulate, preserve and regenerate cells and tissues in mice. The mechanism of action involves photon absorption in the mitochondria (cytochrome-C

oxidase) and ion channels in cells leading to activation of signaling pathways, up-regulation of transcription factors, and increased expression of protective genes (possibly mediated by light absorption by opsins).⁶ Mice have shown an improvement improved memory and learning using LLLT.⁷ Secondary effects of photon absorption include increases in ATP, a brief burst of reactive oxygen species, an increase in nitric oxide, and modulation of calcium levels. Tertiary effects include activation of a wide range of transcription factors leading to improved cell survival, increased proliferation and migration, and new protein synthesis.⁷⁻⁹

Xuan and colleagues have reported on the use of LLLT to treat stroke and traumatic brain injury in experimental

models. These authors demonstrated that mice could significantly improve the neurological severity score, decreasing the lesion volume, and reducing staining for degenerating neurons. Moreover, they found some evidence for neurogenesis in the region of the lesion.⁸

Influence of LLLT on the dynamic equilibrium between lipid peroxidation and tension of the antioxidant defense system in rat tissues (blood, brain, retina, cornea) was evaluated in animals with circulatory cerebral hypoxia induced by occlusion of the left carotid artery. These authors found that their data of the experiment evidenced an antioxidant effect of post-hypoxic LLLT therapy as it reduces intensity of the free radical processes in plasma, cerebral tissues and retina.¹⁰

Therefore, we present the preliminary results on the assessment of brain activity by QEEG and QEEGt in normal subjects, before and after the application of LLLT.

MATERIAL AND METHODS

Subjects

Ten healthy male (n=5) and female (n=5) subjects, 22 to 28 years old, were studied in our laboratory with controlled temperature of 24 to 26°C, noise attenuation, and dimmed lights. A physician and a trained technician were present during each recording session. Subjects were instructed to not drink alcohol, smoke or take any medication the day before the test. Subjects arrived 30 minutes before the session and the physician explained them in detail the test, with a sign informed consent.

Procedure

EEG data were assessed using quantitative EEG (QEEG) and tomographic quantitative EEG (QEEGt) methods. EEGs were recorded using 19 monopolar derivations of the International 10-20 System¹¹ (FP1, FP2, F3, F4, C3, C4, P3, P4, O1, O2, F7, F8, T3, T4, T5, T6, Fz, Cz, Pz) with linked earlobes as a reference. Eye movement artifacts were monitored by use of the electrooculogram (EOG) and all data were recorded (MEDICID-07 System; Neuronic, SA, Cuba). After visual editing to remove artifacts, 48 artifact-free samples were selected, each 2.5 seconds long, for each experimental condition, and were transformed using a fast Fourier transform algorithm to the frequency domain, yielding a power spectrum from 0.78 to 70 Hz with a sampling frequency of 0.39 Hz (178 frequencies), with a 60 Hz notch filter. A detailed description of the QEEG and

QEEGt technique has been published elsewhere.¹²⁻¹⁶

LLLT stimulation was applied with a probe emitting red light at a frequency/power of 635 nm/5mW (technically identical to the Erchonia® EML Laser; Erchonia Corporation, Melbourne, FL) which was continuously moved around the whole skull. Twenty minutes of EEG were recorded before and immediately after the application of 10 minutes of LLLT stimulation. After the treatment session was completed, subjects were interviewed to determine if they perceived any sensations during and after exposure to LLLT.

Statistical analysis

A one-way repeated-measure ANOVA and appropriate post hoc tests were used to compare the differences of EEG band power before and after LLLT stimulation from 19 recording locations in the whole EEG spectra passes. Two-tailed paired t-test was applied to compare the difference of EEG band power before and after LLLT stimulation. A p value < 0.05 was considered statistically significant. All the statistical analysis was performed using the software STATISTICA (StatSoft, Inc. data analysis software system, version 10. www.statsoft.com).

Ethics

The protocol used in this study was approved by the Ethics and Scientific Committees of the Institute of Neurology and Neurosurgery, Havana, Cuba.

RESULTS

Subject 1

QEEG alpha absolute power is presented before and after LLLT stimulation in Figure 1. The yellow color after LLLT stimulation indicates EEG activation, mainly located in posterior regions, lateralized to the left hemisphere, in the alpha band. The 3-dimensional (3D) reconstruction of brain maps makes it easier to visualize EEG changes and location. The QEEG gamma absolute power changes are presented before and after LLLT in Figure 2. Darker red and yellow colors demonstrate EEG activation within the gamma band in anterior regions, lateralized to the left hemisphere, after LLLT stimulation. In Figure 3, QEEGt within the gamma band shows a clear EEG activation after LLLT activation, lateralized to the left hemisphere, in Subject 1. Note that QEEGt is calculated over MRI slices, and the right side corresponds to the left hemisphere. A 3D reconstruction of QEEGt, shows a clear EEG activation in the left hemisphere

after LLLT stimulation in Figure 4.

Figure 1

EEG alpha absolute power before (left) and after LLLT stimulation (right) in Subject 1. The yellow color after LLLT stimulation indicates EEG activation, mainly located in posterior regions, lateralized to the left hemisphere, in the alpha band.

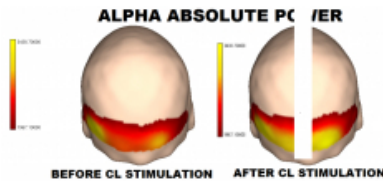


Figure 2

QEEG gamma absolute power before (left) and after LLLT stimulation (right) in Subject 1. Darker red and yellow colors demonstrate EEG activation within the gamma band in anterior regions

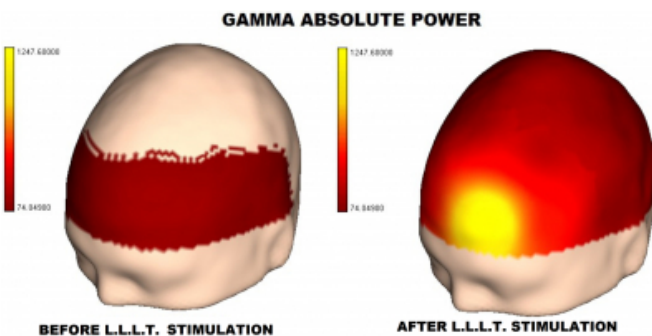


Figure 3

QEEGt within the gamma band (top) shows a clear EEG activation after LLLT activation (bottom) in Subject 1.

QUANTITATIVE ELECTRIC TOMOGRAPHY

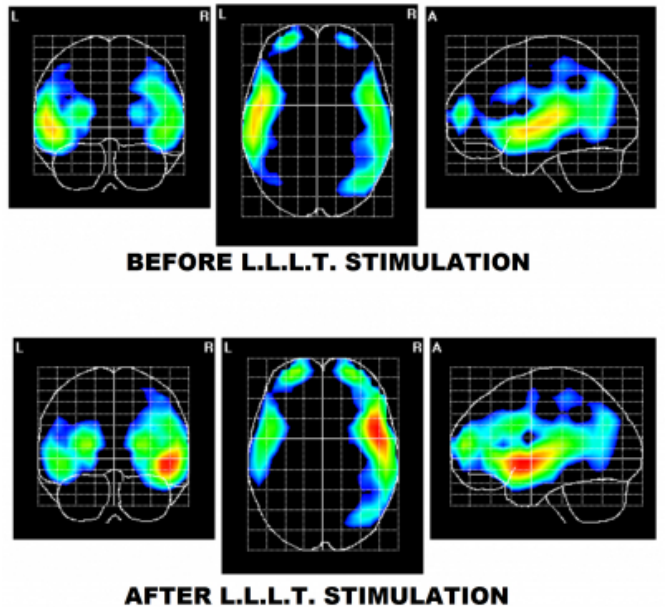
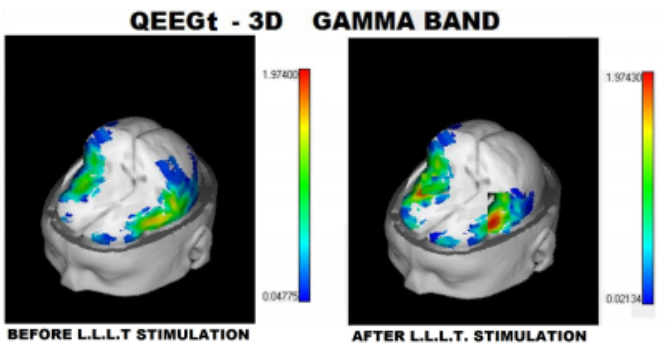


Figure 4

A 3-dimensional reconstruction of QEEGt (left), shows clear EEG activation in the left hemisphere after LLLT stimulation (right) in Subject 1.



Subject 2

QEEG alpha absolute power shows an EEG activation in the right hemisphere, mainly in the temporal lobe, in Figure 5. QEEG within the gamma band shows a clear EEG activation in the right hemisphere, mainly in the temporal region, in Figure 6. QEEGt within the gamma band also shows a clear EEG activation in the right hemisphere, mainly in temporal lobe in Figure 7 although the activation extends up to the frontal and parietal-occipital lobes. Note that QEEGt is calculated over MRI slices, and the left side corresponds to the right hemisphere. In Figure 8, a 3D reconstruction of

QEEGt within the gamma band shows a clear EEG activation in the right hemisphere, mainly in the temporal lobe.

After reviewing the first two subjects, we became aware of the need to focus on the analysis of alpha and gamma bands, before and after LLLT stimulation. The brain maps for alpha and gamma absolute powers (AP) demonstrated clear increments in nine subjects (Figures 9-16). A decrement in alpha and gamma AP after LLLT stimulation only occurred in one subject (Figure 11). It was interesting to note the very similar patterns of activation for the alpha and gamma bands in one subject (Figure 13).

Figure 5

QEEG alpha absolute power before (left) and after LLLT stimulation (right) in Subject 2. EEG activation occurred in the right hemisphere, mainly in the temporal lobe.

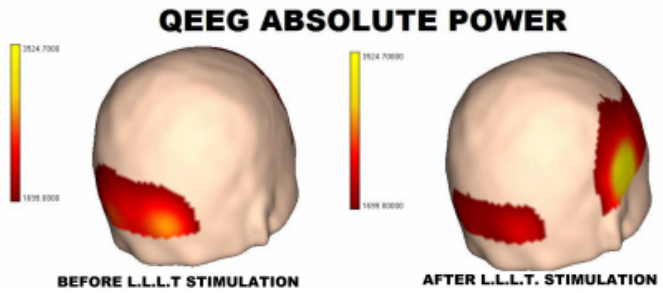


Figure 6

QEEG gamma absolute power before (left) and after LLLT stimulation (right) in Subject 2. EEG activation occurred in the right hemisphere, mainly in the temporal lobe.

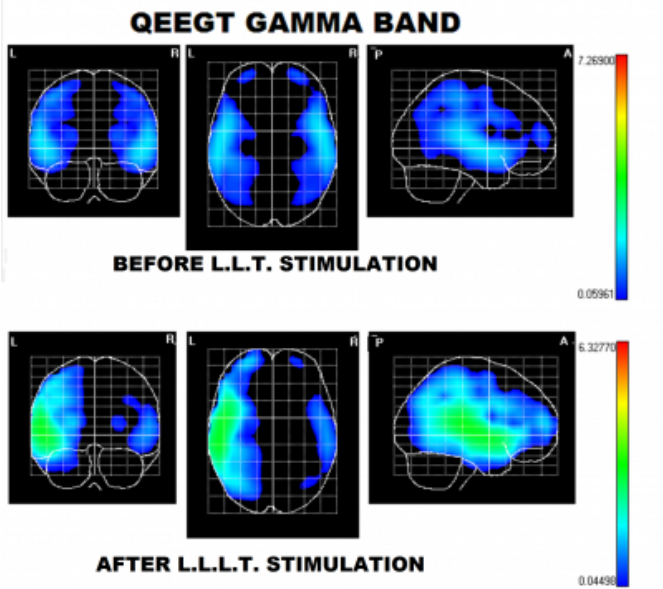


Figure 7

QEEGt within the gamma band (top) shows a clear EEG activation after LLLT activation (bottom) in Subject 2. Activation extends up to the frontal and parietal-occipital lobes.




Figure 8

A 3-dimensional reconstruction of QEEGt (left), shows clear EEG activation in the right hemisphere, mainly in the temporal lobe after LLLT stimulation (right) in Subject 1.

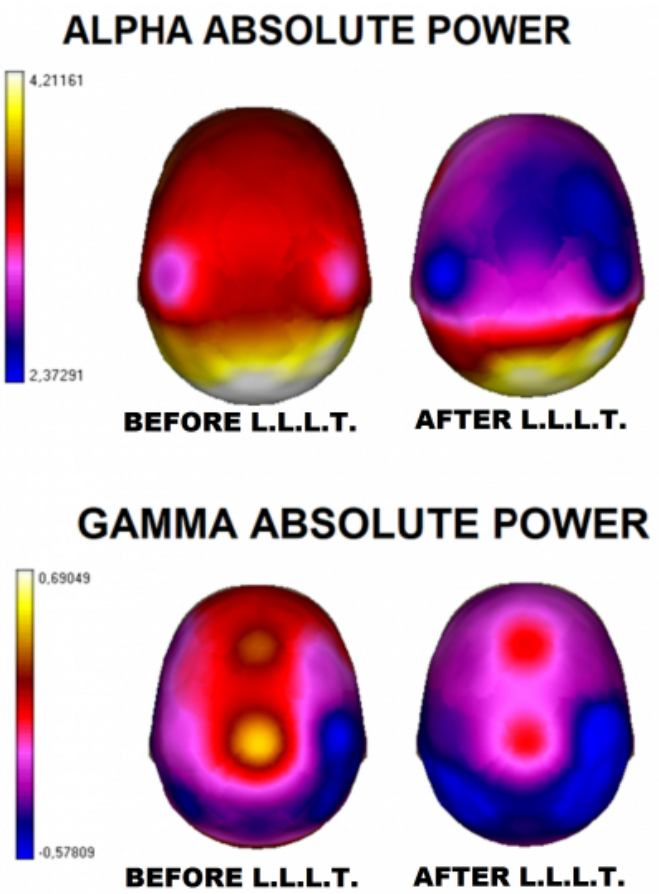


Figure 9

The brain map for alpha and gamma absolute powers (top) demonstrated clear increments after LLLT stimulation (bottom) in this subject.

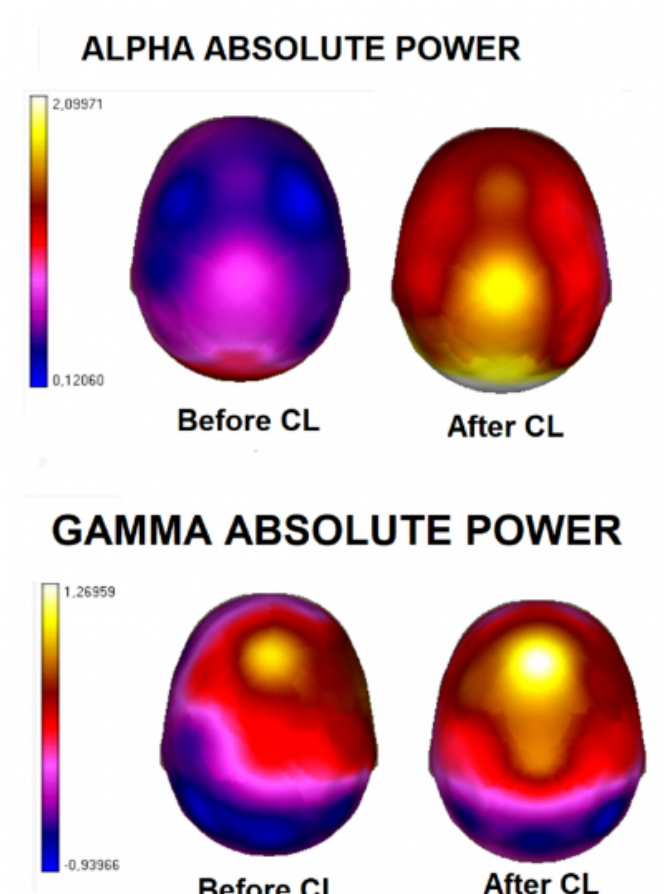


Figure 10

The brain map for alpha and gamma absolute powers (top) demonstrated clear increments after LLLT stimulation (bottom) in this subject.

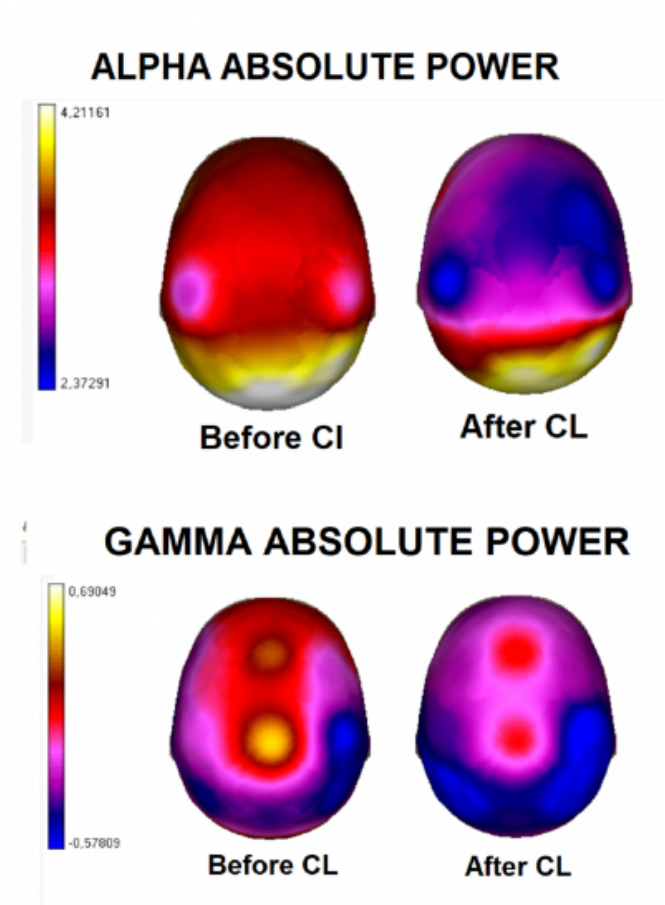


Figure 11

A decrement in alpha and gamma absolute powers (top) occurred after LLLT stimulation occurred in this subject (bottom) after LLLT stimulation

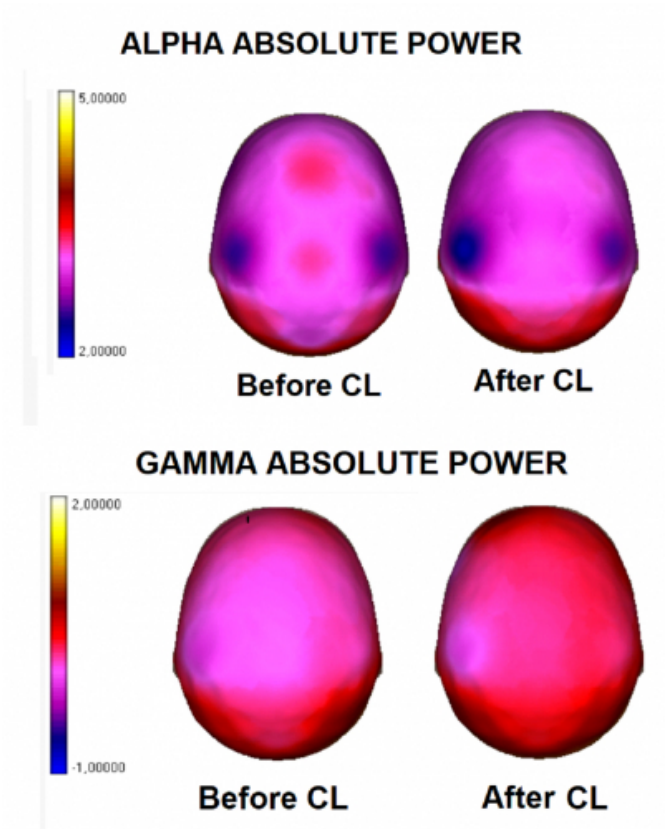


Figure 12

The brain map for alpha and gamma absolute powers (top) demonstrated clear increments after LLLT stimulation (bottom) in this subject.

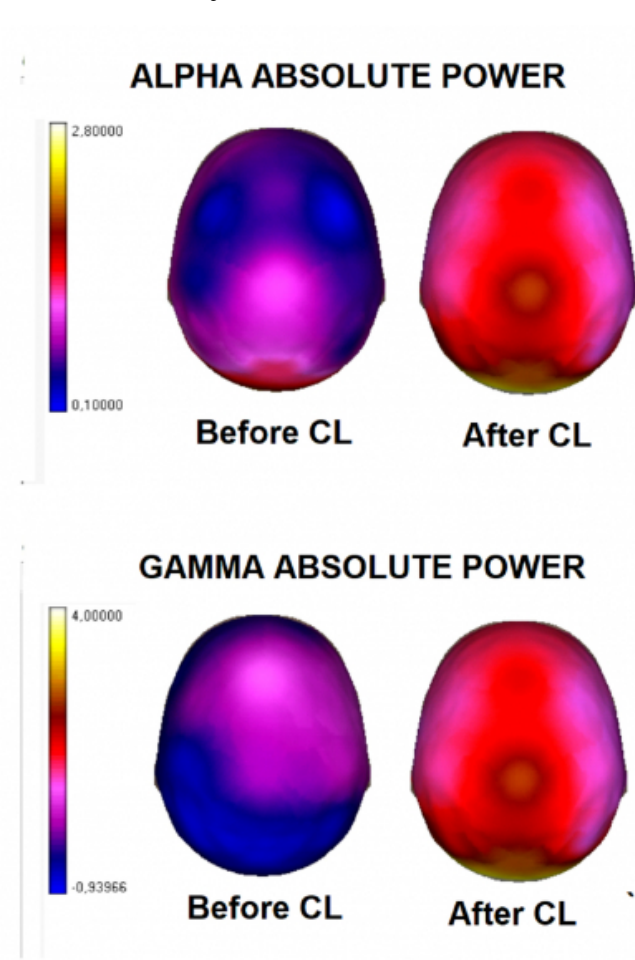


Figure 13

The brain map for alpha and gamma absolute powers (top) demonstrated clear increments after LLLT stimulation (bottom) in this subject. It was interesting to note the very similar patterns of activation for the alpha and gamma bands in this subject

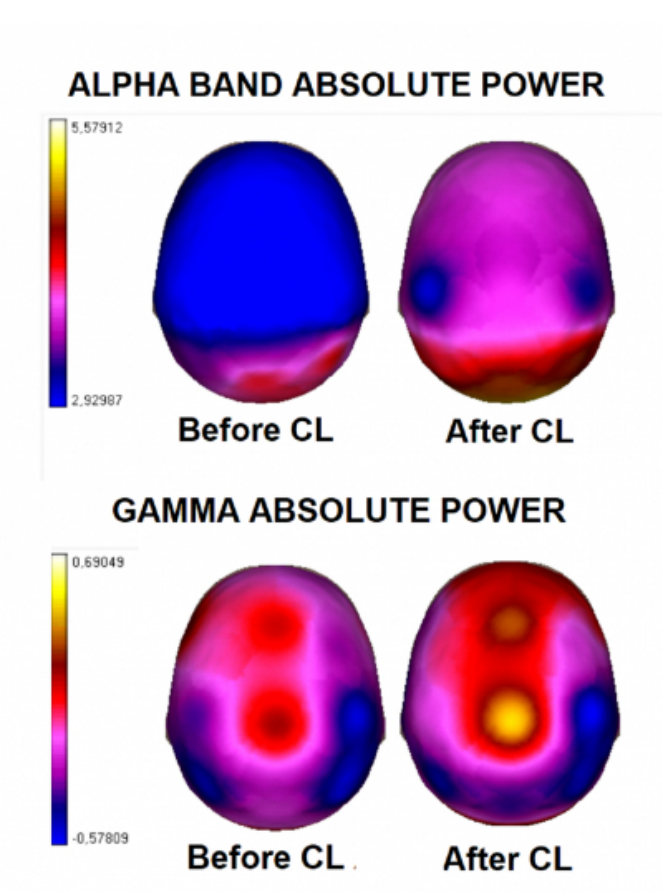
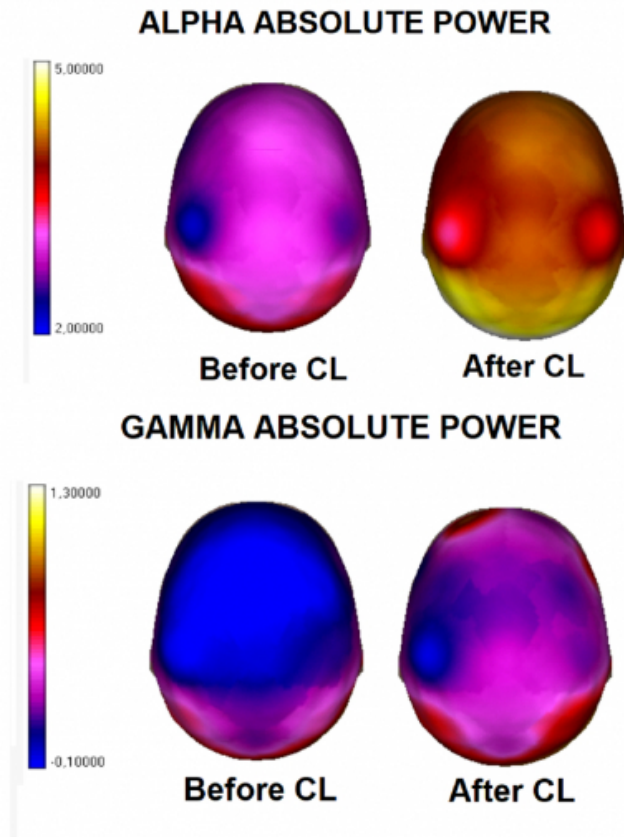


Figure 14

The brain map for alpha and gamma absolute powers (top) demonstrated clear increments after LLLT stimulation (bottom) in this subject.



DISCUSSION

Several clinical trials have affirmed that LLLT has important relevance in neurological diseases, such as stroke, traumatic brain injury, degenerative brain disease, spinal cord injury, and peripheral nerve regeneration; however, several studies have reported negative results leading to controversy regarding the efficacy of LLLT for treating neurologic diseases. Numerous technical factors have been proposed for these non-satisfactory results, such as wavelength, fluence, irradiance, treatment duration, dose pulsing and polarization. Moreover, most of these clinical trials have been developed using clinical scales, and not objective ancillary test to assess brain function.¹⁷ To date, few studies have assessed the effect of LLLT on brain function in normal subjects.¹⁸

EEG is a well-known non-invasive technique which remains one of the main methods in clinical and cognitive neuroscience providing an objective measure of brain function.¹⁸⁻²¹ Both conventional EEG and QEEG provide the necessary time resolution to detect early changes in brain

function after the application of any stimuli.¹²⁻¹⁴ EEG activity can be affected by different stimulation modalities, including visual, auditory, and somatosensory stimulation. It has been proposed that adequate and effective EEG activity is related to cognitive changes in normal subjects and in disease.¹² Moreover, QEEGt allows a reformulation of QEEG techniques in a 3D anatomic framework. Current QEEGt methods permit the calculation of source derivations on magnetic resonance imaging slices. Therefore, the limitations of conventional EEG or topographic QEEG for localizing brain lesions (spatial resolution) have been overcome by the introduction of QEEGt. This is an extension of topographic QEEG, based on maps that correspond to a realistic anatomy.^{15,16}

After careful review of the subjects in our study, we found activation in both the alpha and gamma bands after LLLT. Alpha reactivity is one of the main signs of change in EEG modulation which has been known since the discovery of EEG in humans. In normal, awake, relaxed adults with closed eyes, the dominant brain waves are alpha rhythms distributed mainly in the posterior head region. Alpha rhythms are attenuated by visual attention and mental efforts. It has been proposed that adequate and effective EEG activity is related to cognitive changes in normal subjects and in disease.¹² The typical EEG changes during drowsiness in normal adults are gradual or brisk dropout of alpha rhythms, appearance of desynchronized low-voltage slow waves (2-7 Hz) and emergence of vertex sharp waves.²²⁻²⁴

In contrast, several reports have demonstrated activation of the alpha band during hyperarousal states in normal subjects. During hyperarousal, alpha (10-12.5 Hz), and beta (13-30 Hz) signals were significantly increased compared with those during the control phases.¹⁸ Other authors have noted that sport practice produces an activation of alpha oscillations, which is associated with improved golf putting performance.²⁵ It has been also reported that unconstrained music listening is associated with increased power in all examined frequency bands (including alpha band), as a neural indicator of a mental state that can best be described as a mind-wandering state during which the subjects are "drawn into" the music.²⁶ We recently reported an alpha activation in persistent vegetative state (PVS) patients after zolpidem administration, which is considered a paradoxical arousing effect in these patients, since zolpidem is a known hypnotic. We suggested that this drug effect might be useful in the neuro-rehabilitation of these cases.²⁷⁻²⁹

Activation within the gamma band in our subjects was also very interesting. Gamma- band oscillations are a ubiquitous phenomenon in the nervous system and have been implicated in multiple aspects of cognition. In particular, the strength of gamma oscillations at the time a stimulus is encoded predicts its subsequent retrieval, suggesting that gamma activation may reflect enhanced mnemonic processing.^{30,31} Llinas and co-workers proposed that gamma binding is strongly related to human perception and emotion. From this perspective, gamma-band activity is viewed as serving a broad temporal binding function, where single-cell oscillators and the conduction time of the intervening pathways support large multicellular thalamo-cortical resonance that is closely linked with cognition and subjective experience. Hence, temporal binding is considered as a key influence for cognitive operations by means of fast (gamma band) phase synchrony, reinforcing a unified cognitive-mental space.³²

CONCLUSION

The results of this pilot study demonstrate LLLT stimulation produces EEG activation in both alpha and gamma bands in normal subjects. These results may represent an explanation for its reported effects in neuro-rehabilitation and cognition in neurological diseases. In normal subjects, LLLT may be used to support mental training in learning, sport training, and other daily life activities. Further research should be done with a larger sample of cases to build up a normative data, for comparison with the application of LLLT on the treatment of different neurological diseases, and neuro-rehabilitation. Similar studies should be performed using other neurophysiological techniques, such as evoked potentials, event related potentials, and heart rate variability.

ACKNOWLEDGEMENT

The authors acknowledge the editorial assistance of Dr. Carl S. Hornfeldt, Apothekon, Inc. This research was sponsored by Erchonia Corporation, Melbourne, FL

References

1. Mester E, Szende B, Tota JG. Effect of laser on hair growth of mice. *Kiserl Orvostud.* 1967;19:628-631.
2. Mester E, Spiry T, Szende B, Tota JG. Effect of laser rays on wound healing. *Am J Surg.* 1971;122(4):532-535.
3. Mester E, Szende B, Spiry T, Scher A. Stimulation of wound healing by laser rays. *Acta Chir Acad Sci Hung.* 1972;13(3):315-324.
4. El-Makakey AM, El-Sharaby RM, Hassan MH, Balbaa A. Comparative study of the efficacy of pulsed electromagnetic field and low level laser therapy on mitogen-activated protein kinases. *Biochem Biophys Rep.* 2017;9:316-321.
5. Huang YY, Chen AC, Carroll JD, Hamblin MR. Biphasic dose response in low level light therapy. *Dose Response.* 2009;7(4):358-383.

6. !!! INVALID CITATION !!! {}.
7. Hennessy M, Hamblin MR. Photobiomodulation and the brain: a new paradigm. *J Opt.* 2017;19(1):013003.
8. Xuan W, Huang L, Hamblin MR. Repeated transcranial low-level laser therapy for traumatic brain injury in mice: biphasic dose response and long-term treatment outcome. *J Biophotonics.* 2016;9(11-12):1263-1272.
9. Wu Q, Xuan W, Ando T, Xu T, Huang L, Huang YY, Dai T, Dhital S, Sharma SK, Whalen MJ, Hamblin MR. Low-level laser therapy for closed-head traumatic brain injury in mice: effect of different wave lengths. *Lasers Surg Med.* 2012;44(3):218-226.
10. Shurygina IP, Miliutina NP, Pokudina IO, Prokofev VN, Kussmaul AR, Shkurat TP. Influence of infrared cold laser radiation emission on free radical processes in various tissues of rats with circulatory cerebral hypoxia. *Aviakosm Ekolog Med.* 2009;43(4):51-55.
11. Homan RW, Herman J, Purdy P. Cerebral location of international 10-20 system electrode placement. *Electroencephalogr Clin Neurophysiol.* 1987;66(4):376-382.
12. Machado C, Estévez M, Leisman G, Melillo R, Rodríguez R, DeFina P, Hernández A, Pérez-Nellar J, Naranjo R, Chinchilla M, Garófalo N, Vargas J, Beltrán C. QEEG spectral and coherence assessment of autistic children in three different experimental conditions. *J Autism Dev Disord.* 2015;45(2):406-424.
13. Cuspineda E, Machado C, Galán L, Aubert E, Alvarez MA, Llopis F, Portela L, García M, Manero JM, Avila Y. QEEG prognostic value in acute stroke. *Clin EEG Neurosci.* 2007;38(3):155-160.
14. Cuspineda Bravo ER, Iturria Y, Praderes JC, Melie L, Valdés PA, Virues T, Machado C, Valdés Urrutia L. Noninvasive multimodal neuroimaging for Rasmussen encephalopathy surgery: simultaneous EEG-fMRI recording. *Clin EEG Neurosci.* 2010;41(3):159-165.
15. Machado C, Cuspineda E, Valdés P, Virues T, Llopis F, Bosch J, Aubert E, Hernández E, Pando A, Alvarez MA, Barroso E, Galán L, Avila Y. Assessing acute middle cerebral artery ischemic stroke by quantitative electric tomography. *Clin EEG Neurosci.* 2004;35(3):116-124.
16. Machado C. Quantitative electroencephalographic tomography for assessing acute stroke. *Ann Neurol.* 2001;50:S39-43.
17. Hashmi JT, Huang YY, Osmani BZ, Sharma SK, Naeser MA, Hamblin MR. Role of low-level laser therapy in neurorehabilitation. *PM R.* 2010;2(12 Suppl 2):S292-305.
18. Kawai N, Honda M, Nishina E, Yagi R, Oohashi T. Electroencephalogram characteristics during possession trances in healthy individuals. *Neuroreport.* 2017;28(15):949-955.
19. Besson P, Bandt SK, Proix T, Lagarde S, Jirsa VK, Ranjeva JP, Bartolomei F, Guye M. Anatomic consistencies across epilepsies: a stereotactic-EEG informed high-resolution structural connectivity study. *Brain.* 2017;140(10):2639-2652.
20. Imperatori C, Della Marca G, Amoroso N, Maestoso G, Valenti EM, Massullo C, Carbone GA, Contardi A, Farina B. Alpha/theta neurofeedback increases mentalization and default mode network connectivity in a non-clinical sample. *Brain Topogr.* 2017; Sept 21: Epub ahead of print.
21. Höller Y, Uhl A, Bathke A, Thomschewski A, Butz K, Nardone R, Fell J, Trinka E. Reliability of EEG measures of interaction: a paradigm shift is needed to fight the reproducibility crisis. *Front Hum Neurosci.* 2017;30:11:441.
22. Barry RJ, De Blasio FM. EEG differences between eyes-closed and eyes-open resting remain in healthy ageing. *Biol Psychol.* 2017;129:293-304.

23. Johnsen B, Nøhr KB, Duez CHV, Ebbesen MQ. The nature of EEG reactivity to light, sound, and pain stimulation in neurosurgical comatose patients evaluated by a quantitative method. *Clin EEG Neurosci*. 2017; Aug 1:Epub ahead of print.
24. Bazanova OM, Nikolenko ED, Barry RJ. Reactivity of alpha rhythms to eyes opening (the Berger effect) during menstrual cycle phases. *Int J Psychophysiol*. 2017;May 3:Epub ahead of print.
25. Gallicchio G, Cooke A, Ring C. Practice makes efficient: cortical alpha oscillations are associated with improved golf putting performance. *Sport Exerc Perform Psychol*. 2017;6(1):89-102.
26. Markovic A, Kühnis J, Jäncke L. Task context influences brain activation during music listening. *Front Hum Neurosci*. 2017;11:342.
27. Machado C, Estévez M, Rodríguez R, Pérez-Nellar J, Chinchilla M, DeFina P, Leisman G, Carrick FR, Melillo R, Schiavi A, Gutiérrez J, Carballo M, Machado A, Olivares A, Pérez-Cruz N. Zolpidem arousing effect in persistent vegetative state patients: autonomic, EEG and behavioral assessment. *Curr Pharm Des*. 2014;20(26):4185-4202.
28. Machado C, Estévez M, Pérez-Nellar J, Gutiérrez J, Rodríguez R, Carballo M, Chinchilla M, Machado A, Portela L, García-Roca MC, Beltrán C. Autonomic, EEG, and behavioral arousal signs in a PVS case after zolpidem intake. *Can J Neurol Sci*. 2011;38(2):341-344.
29. Rodríguez-Rojas R, Machado C, Alvarez L, Carballo M, Estevez M, Perez-Nellar J, Pavon N, Chinchilla M, Carrick FR, DeFina P. Zolpidem induces paradoxical metabolic and vascular changes in a patient with PVS. *Brain Inj*. 2013;27(11):1320-1329.
30. Varela FJ. Resonant cell assemblies: a new approach to cognitive functions and neuronal synchrony. *Biol Res*. 1995;28(1):81-95.
31. Headley DB, Weinberger NM. Gamma-band activation predicts both associative memory and cortical plasticity. *J Neurosci*. 2011;31(36):12748-12758.
32. Llinas RR, Leznik E, Urbano FJ. Temporal binding via cortical coincidence detection of specific and nonspecific thalamocortical inputs: a voltage- dependent dye-imaging study in mouse brain slices. *Proc Natl Acad Sci USA*. 2002;99(1):449-454.

Author Information

Calixto Machado, MD, PhD, FAAN

Institute of Neurology and Neurosurgery

Havana, Cuba

Yanin Machado, MD

Institute of Neurology and Neurosurgery

Havana, Cuba

Mauricio Chinchilla, MD

Institute of Neurology and Neurosurgery

Havana, Cuba

Steven Shanks

Erchonia Corporation

Melbourne FL, USA

Humberto Foyaca-Sibat

Head of Neurology and Stroke Unit Faculty of Health Sciences Nelson Mandela Academic Hospital; Walter Sisulu University

Mthatha South Africa