NERVE CONDUCTION VELOCITY AND CROSS-SECTIONAL AREA IN ULNAR NEUROPATHY AT THE ELBOW

SIMON PODNAR, MD, DSc,[1] GREGOR OMEJEC, PT, DSc,[1] and MARKO BODOR, MD[2,3,4]

[1] Institute of Clinical Neurophysiology, University Medical Center Ljubljana, SI-1525 Ljubljana, Slovenia
[2] Department of Physical Medicine and Rehabilitation, University of California Davis, Sacramento, California, USA
[3] Department of Neurological Surgery, University of California San Francisco, San Francisco, California, USA
[4] Interventional Spine and Sports Medicine, Napa, California, USA

Accepted 20 March 2017

ABSTRACT: *Introduction:* In the precise localization of ulnar neuropathy at the elbow (UNE) we have noted discrepancies between electrodiagnostic (EDx) and ultrasonographic (US) findings. We aimed to explore the relationship between the 2 techniques.

Methods: Four study-blind examiners took a history and performed neurologic, EDx, and US examinations of a group of prospectively recruited patients with UNE. They assessed the relationship between ulnar nerve cross-sectional area (CSA) and motor nerve conduction velocity (MNCV).

Results: In 106 patients with UNE at the retrocondylar (RTC) groove, the highest CSA and lowest MNCV were noted in the same short segment. In 54 patients with UNE at the humeroulnar aponeurosis (HUA), the highest CSA and lowest MNCV were noted proximal to the HUA.

Conclusions: MNCV and CSA were highly correlated in UNE. Ulnar nerve slowing proximal to the entrapment at the HUA was surprising, but consistent with previous studies done on carpal tunnel syndrome.

Muscle Nerve **000**:000–000, 2017

Focal neuropathies are diagnosed primarily on the basis of the history and neurologic examination.[1] The diagnosis is also frequently confirmed with an electrodiagnostic examination (EDx). Focal neuropathies are localized on EDx by demonstrating neurophysiologic signs of focal demyelination.[2] These signs are: (1) conduction block; and (2) reduced nerve conduction velocity.[2] In the last decade, high-resolution ultrasonography (US) has improved to the point that it provides an additional method for diagnosing and precisely localizing focal neuropathies.[3] At locations of nerve pathology, US can reveal either nerve enlargement or nerve constriction.

For focal neuropathies, such as ulnar neuropathy at the retrocondylar (RTC) groove of the elbow[4] or fibular neuropathy at the fibular head,[5] typically only nerve enlargement is seen. In demyelinating polyneuropathies, the degree of nerve enlargement has been found to be directly related to the degree of nerve conduction slowing in some studies,[6,7] but not in others.[8,9] In performing EDx and US for ulnar neuropathy at the elbow (UNE), we[10] and others[11] have noted discrepancies between using these 2 techniques when aiming to determine the exact site of pathology. Improving our ability to identify the location of entrapment or compression is likely to lead to better treatment decisions and potentially less-invasive diagnostic techniques.

The aim of this study was to explore the relationship between EDx and US findings in the 2 most common types of UNE: (1) entrapment distal to the medial epicondyle under the humeroulnar ligament; and (2) extrinsic compression at the RTC groove.[4]

METHODS

Patients and Controls. Patients with suspected UNE were prospectively recruited from the Institute of Clinical Neurophysiology, University Medical Center Ljubljana, Slovenia, between April 2012 and October 2014. The inclusion criteria were at least 1 of the following symptoms: (1) continuous numbness or paresthesias in the fourth and fifth finger; (2) weakness of the abductor digiti minimi (ADM) and the first dorsal interosseous (FDI) muscles; or (3) loss of hand dexterity (e.g., dropping small objects, difficulty putting the little finger into a pocket). Exclusion criteria were: (1) previous elbow fracture or surgery; (2) polyneuropathy; or (3) motor neuron disorder. Four investigators took the history and performed the neurologic, EDx, and US examinations. Each part of the evaluation was always performed by the same investigator, who was blinded to the findings of the other parts of the evaluation. The study was approved by the National Ethics Committee of Slovenia, and written informed consent was obtained from all participants before the investigation.

History and Examination. The first examiner took a short history and collected demographic and clinical data using a focused questionnaire.[12] The second examiner

Abbreviations: ADM, abductor digiti minimi; CMAP, compound muscle action potential; CSA, cross-sectional area; D1, D2, D3, and D4, 1-, 2-, 3-, and 4-cm distal to ME; EDx, electrodiagnostic examination; EMG, electromyography; FDI, first dorsal interosseous; HUA, humeroulnar aponeurosis; ME, medial epicondyle; MNCV, motor nerve conduction velocity; MRC, Medical Research Council; P1, P2, P3, P4, P5, and P6, 1-, 2-, 3-, 4-, 5-, and 6-cm proximal to ME; RTC, retrocondylar; SNAP, sensory nerve action potentials; SSNCS, short-segment nerve conduction study; UNE, ulnar neuropathy at the elbow; US, ultrasonography

Key words: nerve conduction studies; nerve conduction velocity; nerve cross-sectional area; ulnar neuropathy at the elbow; ultrasonography

This study was supported by the Republic of Slovenia Research Agency (Grant No. P3-0338 to S.P. and G.O.) and by the Napa Medical Research Foundation [a non-profit 501(c)3 organization] (to M.B.).

This article was published online on 15 April 2017. After online publication, updates were made to the text. This notice is included in the online and print versions to indicate that both have been corrected on 28 April 2017.

Correspondence to: S. Podnar; e-mail: simon.podnar@kclj.si

© 2017 Wiley Periodicals, Inc.
Published online 00 Month 2017 in Wiley Online Library (wileyonlinelibrary.com). DOI 10.1002/mus.25655

performed a neurologic examination of both upper limbs. He graded muscle wasting and estimated muscle strength using the Medical Research Council (MRC) scale,[13] and then tested light-touch and pin-prick perception in both hands.

Preoperative EDx Studies. The third examiner performed ulnar nerve conduction studies (NCSs) across the elbow with the patient supine using a standard electromyography (EMG) system (Nicolet Synergy, Natus Medical, Inc., San Carlos, California). With the elbow flexed at 90°, the ulnar nerve was stimulated at the wrist, and at 6 positions from 4 cm distal to 6 cm proximal to medial epicondyle (ME) separated by 2-cm segments, as described in detail elsewhere.[4] During these SSNCSs, compound muscle action potentials (CMAPs) were recorded separately from ADM and FDI muscles. In addition, in all controls and in 91 UNE patients, the examiner also stimulated the ulnar nerve at the wrist and recorded responses by using a bar recording electrode at the elbow markers (mixed ulnar study). In all patients, ulnar antidromic sensory nerve action potentials (SNAPs) from the fifth finger, and concentric needle EMG of the hand and forearm muscles were also performed.[10]

Using SSNCSs, UNE was diagnosed and localized to a 2-cm segment with the most pronounced motor nerve conduction velocity (MNCV) slowing (i.e., below the lower limit of normal, 31 m/s, for a 2-cm segment), or CMAP amplitude drop in the elbow area (i.e., above the upper limit of normal, 12%).[4,14] The fifth finger SNAP was considered abnormal when $<13\,\mu V$.[14]

Ultrasonography. During US examination, the fourth examiner measured the ulnar nerve CSA at the distal wrist crease and at each of 6 markers across the elbow using an US device (ProSound Alpha 7, Hitachi Aloka Medical, Ltd., Tokyo, Japan) with a 4–13-MHz linear-array transducer. He excluded the hyperechoic rim from CSA measurements using a trace method at 13 MHz. To localize the lesion under the humeroulnar aponeurosis (HUA) more precisely, he also measured CSA at 1 and 3 cm distal to the ME (D1 and D3) in all patients with UNE distal to the ME.[4]

Using US, UNE was diagnosed and localized as follows: (1) at the point of ulnar nerve constriction when CSA just proximal and distal to that location was at least $2\,mm^2$ larger; (2) at the first marker distal to ulnar nerve enlargement (CSA > our upper limit of normal) in cases of maximal CSA (CSA_{max}) distal to the ME; or (3) at the location of CSA_{max} in ulnar nerves with CSA_{max} at or proximal to the ME.[4]

Localization. In using SSNCSs and US, if the lesion was localized distal to the ME, UNE under the HUA was diagnosed. If the lesion was localized proximal to or at the ME, UNE at the RTC groove was diagnosed. If the lesion could not be localized, UNE without clear localization was diagnosed.[4]

Intraoperative EDx. In patients with UNE entrapment under the HUA, surgical release of the HUA was performed, and most of these patients had intraoperative EDx studies.[15] The surgical procedure and intraoperative studies were performed in a bloodless operative field with a sphygmomanometer cuff applied to the upper arm and inflated to 250 mm Hg for 20 min. Immediately after cubital tunnel decompression, intraoperative near-nerve SSNCSs of the ulnar nerve were performed.[16] We used identical patient and elbow positions and the same EMG system as used for the preoperative EDx studies. For stimulation, the surgeon applied electrical currents of 5–25 mA and 0.1-ms duration using a custom-made, thin-wired bipolar stimulator with an interelectrode distance of 1 cm.[17] The surgeon performed intraoperative near-nerve stimulation of the ulnar nerve at the same positions as in the preoperative studies (except for stimulation at the wrist and P6), with simultaneous recording of CMAPs from the ADM and the FDI muscles.

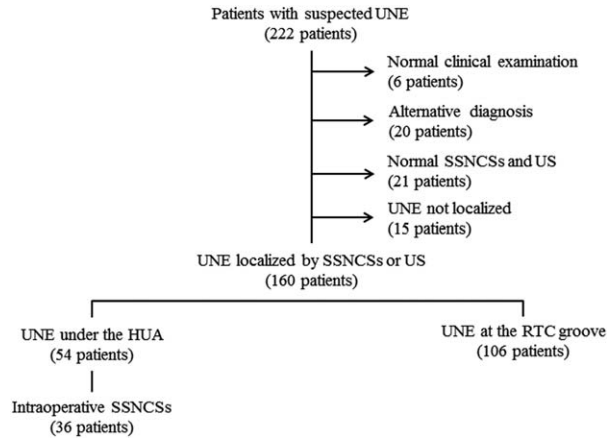

FIGURE 1. Flowchart of the recruitment of 160 arms with clinical diagnosis of ulnar neuropathy at the elbow (UNE) as confirmed by short-segment nerve conduction studies (SSNCSs) or ultrasonography (US) included in the present study. UNE localized distal to the medial epicondyle (ME) [UNE under the humeroulnar aponeurosis (HUA)] or proximal to ME [UNE at the retrocondylar (RTC) groove] was analyzed. Only patients with UNE under the HUA were offered surgical treatment with intraoperative SSNCSs.[15]

Statistics. Of the patients with suspected UNE, we excluded from further analyses all patients with: (1) alternative diagnoses, including C8 radiculopathy and ulnar neuropathy at the wrist; (2) a normal neurologic examination; and (3) normal SSNCSs and US studies (Fig. 1). All NCV and CSA measurements were performed only once, except for repetition in case of doubt. Distributions of continuous variables were presented as the median, 5th and 95th percentiles and range, or mean (standard deviation). As no significant difference ($P > 0.05$) in UNE localization and MNCV was found on recordings from the ADM and the FDI muscles, we used ADM recordings for further analyses. For UNE under the HUA we plotted ulnar nerve conduction velocities vs. localization along the ulnar nerve for preoperative and intraoperative studies and aligned them with ulnar nerve CSAs. Separately we also plotted the same variables for UNE at the RTC groove, but without intraoperative studies (as these patients did not undergo surgery). Correlations between variables were calculated as Spearman correlation coefficients. All tests were performed at a significance level of $\alpha = 0.05$ (2-sided).

RESULTS

Patients and Controls. After exclusion of 62 of 222 patients with suspected UNE, we analyzed data obtained from 160 patients with UNE, as confirmed and localized by SSNCSs or US studies (Fig. 1). We localized UNE at the HUA in 54 patients and at the RTC groove in 106 patients (Table 1).

Table 1. Basic demographic data and $SSNCV_{min}$ and CSA_{max} in patients with UNE

	UNE patients	
	HUA	RTC
Number (*n*)	54	106
Number of men (%)	42 (78)	62 (58)
Age [mean (SD), range, in years]	61 (12), 34–89	45 (14), 15–84
Motor $SSNCV_{min}$ [mean (SD), range, in m/s]	12 (7), 2–29	19 (6), 4–31
Mixed $SSNCV_{min}$ – mean (SD), range, in m/s]	18 (7), 8–29	24 (8), 7–40
CSA_{max} [mean (SD), range, in mm^2]	20 (8), 7–37	12 (3), 6–20

HUA column: ulnar nerve entrapment under humeroulnar aponeurosis (HUA); RTC column: ulnar nerve compression in the retrocondylar (RTC) groove. $SSNCV_{min}$, lowest short-segment nerve conduction velocity; CSA_{max}, highest per-patient cross-sectional area; UNE, ulnar neuropathy at the elbow.

UNE under the Humerulnar Aponeurosis. In patients with UNE under the HUA, significantly lower MNCV and higher CSA values were found at the D2/ME (the first 2 cm distal to the medial epicondyle) segment compared with neighboring short segments, both preoperatively and intraoperatively (Table 2, and Figs. 2 and 3). We found a significant negative correlation between MNCV at D2/ME and CSA at point D1; that is, the larger the nerve, the slower the conduction velocity in the 2-cm segment distal to the medial epicondyle (Table 3). When seen on US or at time of surgery, ulnar nerve constriction was noted at points D3 or D2 (Fig. 2), located at the middle or proximal end of the D4/D2 segment. MNCV at this location was surprisingly not as low as compared with the more proximal D2/ME segment (Table 2, and Figs. 2 and 3). Thus, at the location of nerve entrapment at the HUA, slowing was not as evident as it was between that location and the medial epicondyle—that is, at the level of ulnar nerve thickening proximal to ulnar nerve constriction (minimal CSA) (Fig. 4).

In all 29 of the 36 patients with intraoperatively recordable CMAPs from the ADM or FDI muscle, the preoperative diagnosis and localization of UNE distal to the medial epicondyle was confirmed by the intraoperative studies (Fig. 4).[4,14] Furthermore, we did not find significant differences between preoperative and intraoperative MNCVs. Although preoperative MNCVs were significantly lower in the D4/D2 and D2/ME segments of constricted compared with non-constricted nerves (Table 2 and Fig. 3), no such difference was found intraoperatively.

Table 2. Comparison of ulnar motor nerve conduction velocities and cross-sectional areas in patients with ulnar neuropathy at the elbow

Motor nerve conduction velocities (m/s)				Nerve cross-sectional areas (mm^2)			
Segment	Mean (SD), range	Comparison	*P*-value	Marker	Mean (SD), range	Comparison	*P*-value
HUA constricted—percutaneous				HUA constricted			
D4/D2	26.3 (13.7), 4–50	vs. D2/ME	<0.001*	D3	9.1 (3.4), 3–15	vs. D1	<0.001*
D2/ME	10.8 (5.5), 3–21	vs. ME/P2	<0.001*	D1	18.4 (5.7), 11–33	vs. P1	0.015*
ME/P2	28.7 (9.4), 12–44			P1	14.2 (4.1), 9–23		
HUA constricted—intraoperative							
D4/D2	24.0 (17.3), 4–67	vs. D2/ME	0.206				
D2/ME	18.1 (13.2), 5–50	vs. ME/P2	0.006*				
ME/P2	31.3 (10.7), 13–44						
HUA non-constricted—percutaneous				HUA non-constricted			
D4/D2	37.9 (17.6), 3–67	vs. D2/ME	<0.001*	D3	7.8 (2.5), 5–18	vs. D1	<0.001*
D2/ME	19.2 (11.6), 2–50	vs. ME/P2	0.014*	D1	17.6 (9.5), 6–38	vs. P1	0.53
ME/P2	27.7 (15.0), 6–57			P1	15.1 (6.5), 7–29		
HUA non-constricted—intraoperative							
D4/D2	28.3 (12.0), 9–50	vs. D2/ME	<0.001*				
D2/ME	14.7 (6.7), 7–33	vs. ME/P2	<0.001*				
ME/P2	32.9 (13.6), 13–67						
RTC percutaneous				RTC			
D2/ME	41.6 (11.7), 17–67	vs. ME/P2	<0.001*	D1	8.9 (2.1), 5–16	vs. P1	<0.001*
ME/P2	27.6 (13.5), 5–67	vs. P2/P4	<0.001*	P1	10.7 (2.7), 6–19	vs. P3	<0.001*
P2/P4	38.5 (18.1), 4–67			P3	9.4 (2.4), 4–20		

D4, D2, ME, P2, and P4 indicate points from 4 cm distal to 4 cm proximal to medial epicondyle (ME); similarly, D4/D2, D2/ME, ME/P2, and P2/P4 indicate 2-cm segments. HUA, humeroulnar aponeurosis; RTC, retrocondylar (groove); ME, medial epicondyle.

**Statistically significant.*

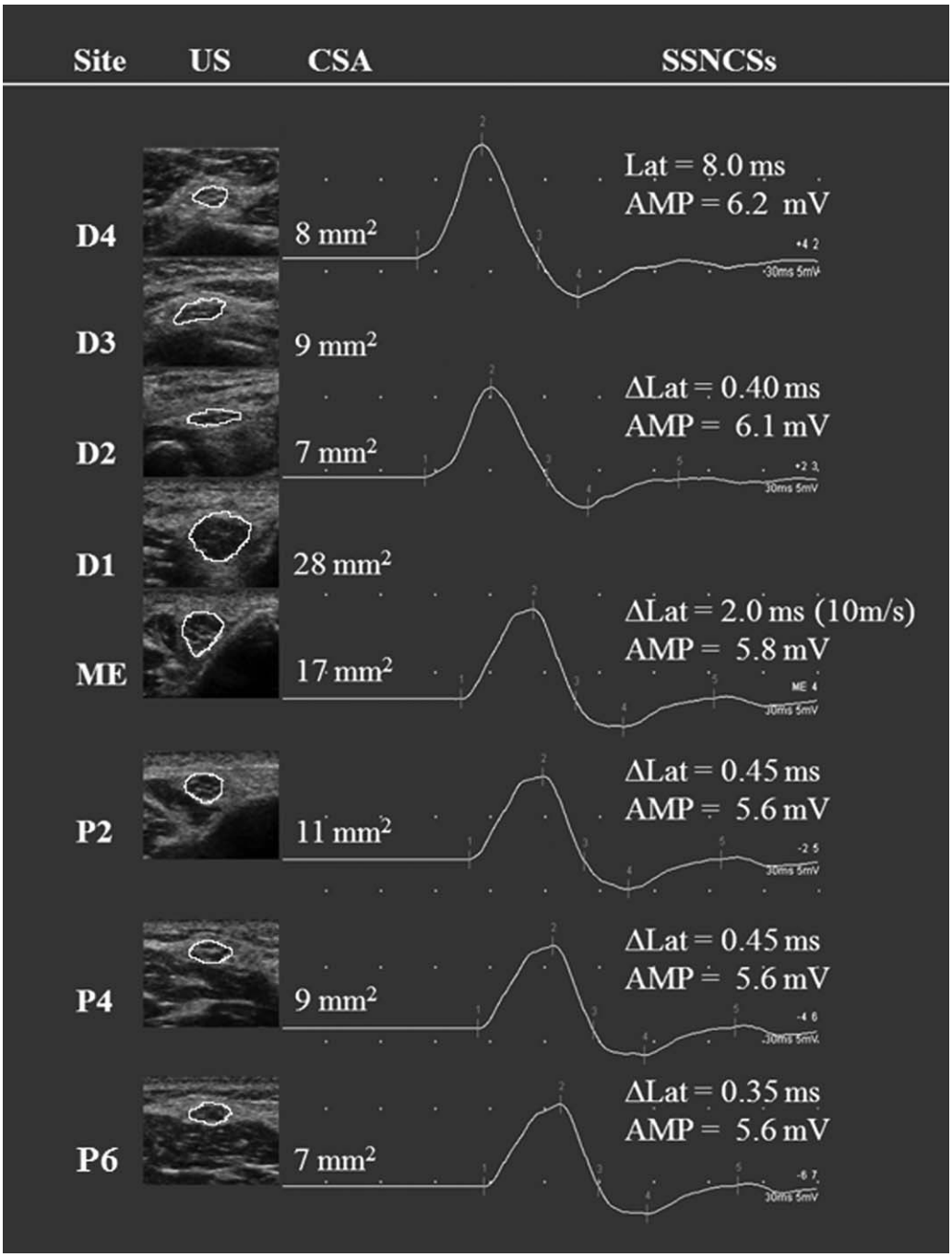

FIGURE 2. Ultrasonography (US) and short-segment nerve conduction study (SSNCS) findings in a 58-year-old man. Ulnar nerve cross-sectional areas (CSAs) were measured and ulnar nerve stimulated (see left column) at the medial epicondyle (ME), 1–4 cm distal to ME (D1–D4), and 2–6 cm proximal to ME (P2–P6). Compound motor action potentials (CMAPs) recorded from the abductor digiti minimi (ADM) muscle are shown. For stimulation at D4, the CMAP latency (Lat) is shown, and for other sites the increase in latency compared with sites 2 cm distally (latency difference: ΔLat) are shown. Ulnar nerve US cross-sectional views, CSAs, and CMAP amplitudes (Amp) are also shown. In this arm, US constriction localized the ulnar nerve lesion to the D2 site, and SSNCSs (ΔLat > 0.65 ms, see Omejec and Podnar[14] to the D2/ME segment. Findings are characteristic for an ulnar neuropathy located under the humeroulnar aponeurosis.

UNE at the Retrocondylar Groove. In patients with UNE at RTC groove, the ME/P2 segment had the lowest MNCV and the highest CSA (Tables 2 and 3, and Fig. 5); that is, the ulnar nerve was largest and conducted most slowly in the segment 2 cm proximal to the medial epicondyle (Fig. 4).

Similarly, there was a significant correlation between slowing of MNCV over a 10-cm segment across the elbow and nerve enlargement ($r = -0.465$; $P < 0.0001$).

Mixed ulnar nerve studies were performed in 91 UNE patients; we excluded from analysis 22

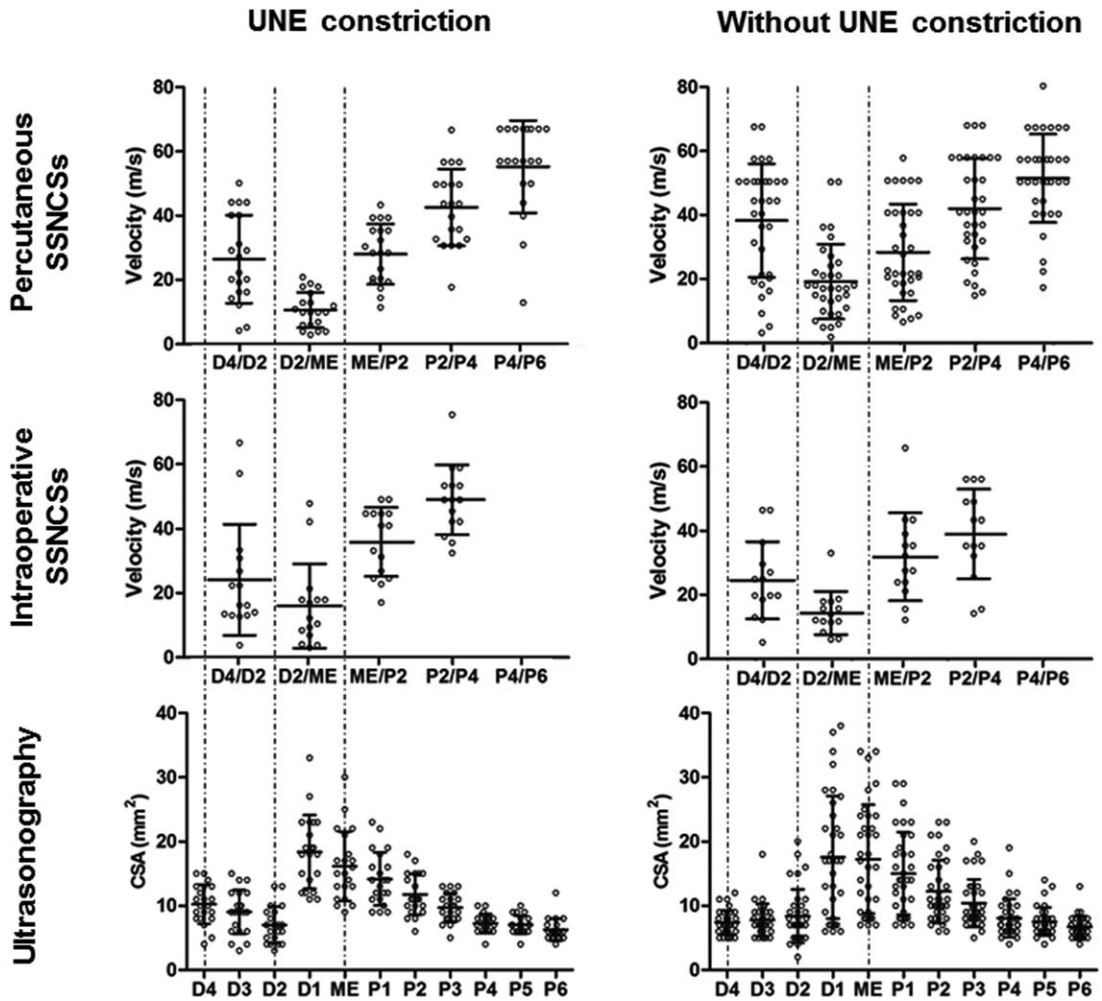

FIGURE 3. Distribution (mean, SD) of ulnar motor nerve conduction velocities and cross-sectional areas (CSAs) in 54 patients with ulnar neuropathy at the elbow (UNE) under the humeroulnar aponeurosis (HUA). The first column shows UNE with ulnar nerve constriction 2 or 3 cm distal (markers D2 or D3) to the medial epicondyle (ME), as demonstrated by ultrasonography (US). The second column shows UNE under the HUA without ulnar nerve constriction (i.e., nerve swelling observed proximal, but not distal, to site of entrapment). The first row shows motor nerve conduction velocities obtained via percutaneous short-segment nerve conduction studies (SSNCSs), and the second via intraoperative SSNCSs. The third row shows CSAs of the ulnar nerves as obtained by US at 1-cm intervals proximal (P1–P6) and distal (D1–D4) to the ME. CSAs at P1, P3, and P5 were not measured directly, but were calculated as the mean CSA of markers just proximal and distal.

UNE patients with non-recordable mixed-nerve responses proximal to D4. There was no significant correlation between mixed NCV across the elbow and CSA_{max} ($r = -0.118$; $P < 0.338$).

DISCUSSION

We believe that ulnar neuropathy at the RTC groove is caused by extrinsic ulnar nerve compression. This most commonly occurs due to inappropriate elbow positioning on a hard surface, as observed in the non-dominant arms of young clerks and students holding a computer mouse in their right (dominant) arm.[18] For this more common variety of UNE,[4] we expected to find a strong correlation between ulnar nerve enlargement and slowing, and this was indeed the case for both 2- and 10-cm-segment MNCV.

By contrast, UNE under the HUA occurs in older manual laborers.[18] In these individuals, we believe years of wear and tear cause transformation of the thin retinaculum of the cubital tunnel into a tough fibrous band (the HUA) that entraps the ulnar nerve. This is supported by the following observations: (1) ulnar nerve constriction resulting in a characteristic hourglass appearance was observed in more than half of these arms by US; (2) our surgeons operating on these patients reported an unusually tough and thick HUA that was more difficult to transect than usual; (3) our surgery patients with elbow and forearm pain reported immediate pain relief after section of the HUA; (4) during an average 2.5-year follow-up period after isolated HUA transection, 82% of our patients remained improved, 60% markedly or

Table 3. Correlations between ulnar motor nerve conduction velocities for 2-cm segments (e.g., D4/D2, D2/ME) and cross-sectional areas at markers in the middle of the segments (e.g., D3, D1) for patients with ulnar neuropathy at the elbow

		Correlation (*P*-value)	
Segment	Marker	HUA	RTC
D4/D2	D3	−0.143 (0.300)	0.002 (0.980)
D2/ME	D1	−0.318 (0.019*)	−0.161 (0.099)
ME/P2	P1	−0.158 (0.254)	−0.211 (0.030*)
P2/P4	P3	−0.298 (0.029*)	−0.094 (0.340)
P4/P6	P5	0.034 (0.806)	−0.233 (0.018*)

Motor nerve conduction velocities were obtained during preoperative percutaneous short-segment nerve conduction studies. Short-segment motor nerve conduction velocities correlated with cross-sectional areas ultrasonographically measured in the middle of the segments. HUA, humeroulnar aponeurosis; RTC, retrocondylar groove; D4, D2, ME, P2, and P4 indicate points ranging from 4 cm distal to 4 cm proximal to medial epicondyle (ME); D4/D2, D2/ME, ME/P2, and P2/P4 indicate 2-cm segments.

**Statistically significant.*

completely so, and 22% partially; (5) clinical improvement was supported by doubling of the ulnar CMAP amplitude and MNCV in the most critical segment; and (6) clinical improvement was supported by significant increases in ulnar nerve CSA in constricted regions, and reductions in enlarged ulnar nerve segments (unpublished data).

In the present study, we expected to find a strong correlation between ulnar nerve constriction and slowing, but this was not the case. In both types of UNE, we found the highest degree of motor nerve slowing at the location where the nerve was most enlarged (Fig. 4). This means that, for UNE at the HUA, motor nerve slowing was most affected proximal to the location of nerve entrapment under the HUA seen on US or at time of surgery.

In the 1930s, experiments on frog sciatic nerves showed that nerves can withstand extremely high uniform compressive forces in isolation without permanent damage.[19] However, in the presence of a pressure gradient and shear forces, endoneurial fluid is squeezed out of the nerve, resulting in interstitial edema, apposition of fibers and cellular elements, injury to the myelin, lengthening of internodes, and compromise of nerve function.[20] This mechanism could explain why we found a greater degree of nerve conduction slowing just proximal to the site of compression.

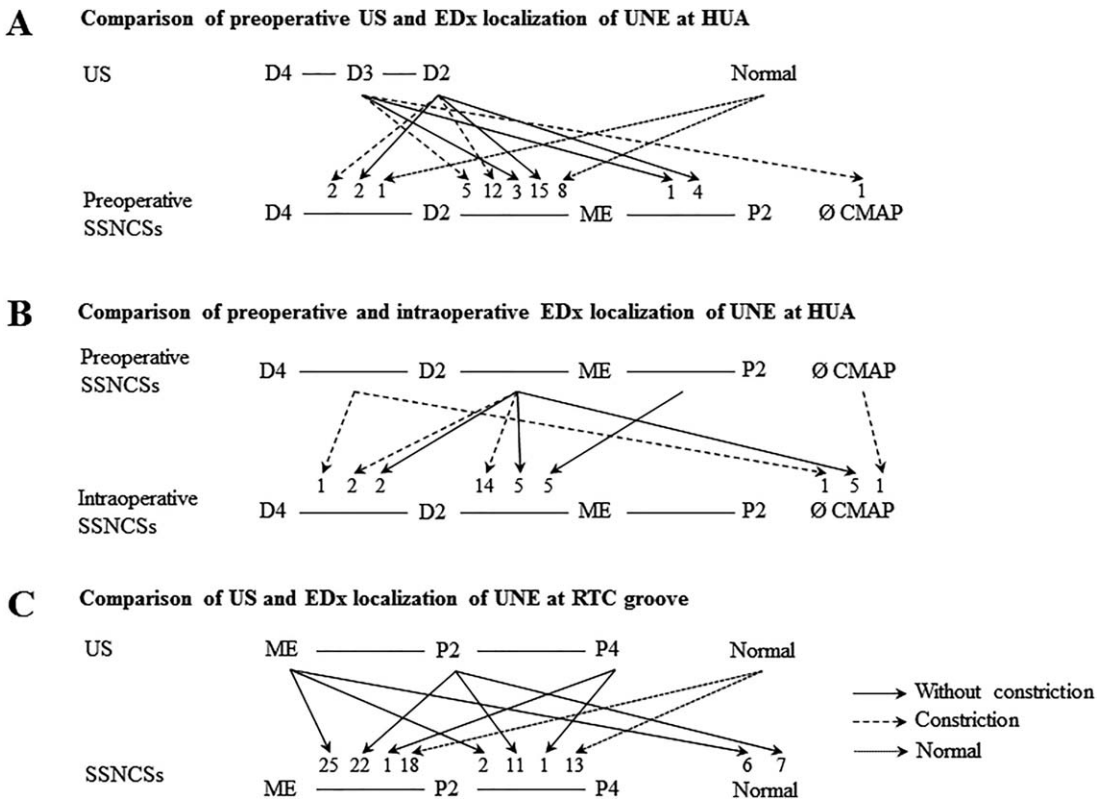

FIGURE 4. Comparison of ultrasonographic (US) and electrodiagnostic (EDx) localization of ulnar neuropathy at the elbow (UNE) at the humeroulnar aponeurosis (HUA) before surgical decompression **(A)**, and for UNE at the retrocondylar (RTC) groove **(C)**. Comparison of preoperative vs. intraoperative short-segment nerve conduction studies (SSNCSs) for UNE at the HUA **(B)** is also shown. Numbers below arrowheads indicate number of patients. With SSNCSs, compound motor action potentials (CMAPs) were recorded from the abductor digiti minimi (ADM) muscles. Ø CMAP: CMAP non-recordable; D1, D2, D3, D4: points 1–4 cm distal to ME; P1, P2, P4: points 1–4 cm proximal to ME.

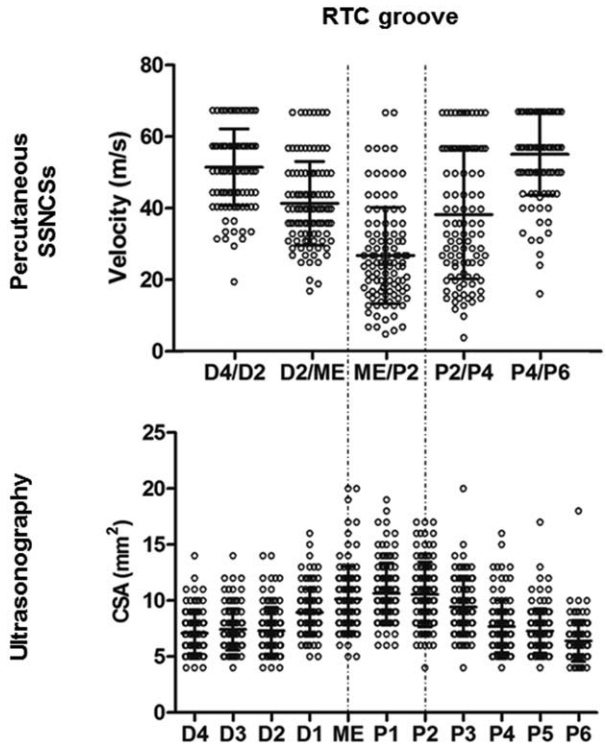

FIGURE 5. Distribution (mean, SD) of motor nerve conduction velocities and cross-sectional areas (CSAs) in 108 patients with ulnar neuropathy of the elbow at the retrocondylar (RTC) groove. (Top) Motor nerve conduction velocities obtained via percutaneous short-segment nerve conduction studies (SSNCSs). (Bottom) CSAs of the ulnar nerves obtained by ultrasonography. Horizontal axis shows points at the medial epicondyle (ME), 1-cm intervals proximal to ME (P1–P6) and distal to ME (D1–D4). Ulnar nerve CSAs at P1, P3, and P5 were not measured directly, but were calculated as the average of CSA at markers just proximal and distal.

This explanation would also apply to median neuropathy at the wrist (carpal tunnel syndrome, or CTS). Indeed, we found interesting parallels between our findings and the findings from a short-segment study of CTS by Kimura.[21] In all 3 of his case examples, selected from a group of 172 symptomatic hands, sensory NCV was most affected under the middle to distal flexor retinaculum, whereas motor NCV was most affected 1–5 cm proximally (see Figs. 6–8 in the Kimura study.[21]

The reason sensory vs. motor slowing was noted at different locations in Kimura's study[21] may have to do with anterograde axonal transport, which is expected to be much greater in motor axons that have to support many metabolically active neuromuscular junctions innervated by a single neuron. This could result in massive swelling of nerve fibers proximal to the point of entrapment, with myelin damage and nerve conduction slowing.

To exclude possible technical artifacts inherent to percutaneous stimulation (i.e., spurious spread of stimulation current to neighboring nerve segments), we also performed intraoperative SSNCSs, using low-intensity currents applied directly to the exposed ulnar nerve. These intraoperative studies confirmed the preoperative EDx and US findings.

Our data showing that nerve conduction slowing was most affected proximal to the location of entrapment for UNE at the HUA has potential implications for surgery. Specifically, patients having the greatest degree of ulnar nerve slowing in the 2-cm segment between the medial epicondyle and the HUA would appear to be good candidates for consideration of surgical release of the HUA. Our findings would be worth investigating further for other nerves and sites of entrapment that are diagnosed with motor SSNCSs and/or US.

A limitation of our study is that we were unable to assess differences in location of slowing between motor and sensory fibers at the HUA because only a few of our patients had recordable mixed-nerve responses and none had orthodromic sensory responses proximal to the level of entrapment. Another limitation is that we did not perform intraoperative NCSs in all patients with UNE localized distal to the ME.

In conclusion, using US and motor SSNCSs we found the greatest degree of MNCV slowing in segments with the highest CSA. This was true for compression at the RTC groove and for entrapment under the HUA. We also found that MNCV was most affected proximal to the level of entrapment in UNE at the HUA, with potential implications for surgery and the evaluation and treatment of other entrapment neuropathies. The mechanism for this is not clear.

The authors thank Dr. Tomaž Žgur for performing neurologic examinations, Alenka Dremelj for subject recruitment and assistance with nerve conduction studies, and Yvette Uribe for help with the literature search and manuscript preparation.

REFERENCES

1. Stewart JD. Focal peripheral neuropathies, 4th ed. Vancouver: JBJ; 2010.
2. Kimura J. Electrodiagnosis in diseases of nerve and muscle: principles and practice, 3rd ed. New York: Oxford University Press; 2001.
3. Beekman R, Visser LH, Verhagen WI. Ultrasonography in ulnar neuropathy at the elbow: a critical review. Muscle Nerve 2011;43:627–635.
4. Omejec G, Podnar S. Precise localization of ulnar neuropathy at the elbow. Clin Neurophysiol 2015;126:2390–2396.
5. Tsukamoto H, Granata G, Coraci D, Paolasso I, Padua L. Ultrasound and neurophysiological correlation in common fibular nerve conduction block at fibular head. Clin Neurophysiol 2014;125:1491–1495.
6. Zaidman CM, Al-Lozi M, Pestronk A. Peripheral nerve size in normals and patients with polyneuropathy: an ultrasound study. Muscle Nerve 2009;40:960–966.
7. Hobson-Webb LD. Neuromuscular ultrasound in polyneuropathies and motor neuron disease. Muscle Nerve 2013;47:790–804.
8. Scheidl E, Böhm J, Simó M, Rózsa C, Bereznai B, Kovács T, *et al.* Ultrasonography of MADSAM neuropathy: focal nerve enlargements at sites of existing and resolved conduction blocks. Neuromuscul Disord 2012;22:627–631.
9. Beekman R, van den Berg LH, Franssen H, Visser LH, van Asseldonk JTH, Wokke JHJ. Ultrasonography shows extensive nerve enlargements in multifocal motor neuropathy. Neurology 2005;65:305–307.
10. Omejec G, Žgur T, Podnar S. Diagnostic accuracy of ultrasonographic and nerve conduction studies in ulnar neuropathy at the elbow. Clin Neurophysiol 2015;126:1797–1804.

11. Simon NG, Ralph JW, Poncelet AN, Engstrom JW, Chin C, Kliot M. A comparison of ultrasonographic and electrophysiologic "inching" in ulnar neuropathy at the elbow. Clin Neurophysiol 2015;126: 391–398.
12. Mondelli M, Padua L, Giannini F, Bibbò G, Aprile I, Rossi S. A self-administered questionnaire of ulnar neuropathy at the elbow. Neurol Sci 2006;27:402–411.
13. O'Brien M. Aids to the examination of the peripheral nervous system, 5th ed. Philadelphia: Saunders; 2010.
14. Omejec G, Podnar S. Normative values for short-segment nerve conduction studies and ultrasonography of the ulnar nerve at the elbow. Muscle Nerve 2015;51:370–377.
15. Omejec G, Božikov K, Podnar S. Validation of preoperative nerve conduction studies by intraoperative studies in patients with ulnar neuropathy at the elbow. Clin Neurophysiol 2016;127:3499–3505.
16. Campbell WW, Sahni SK, Pridgeon RM, Riaz G, Leshner RT. Intraoperative electroneurography: management of ulnar neuropathy at the elbow. Muscle Nerve 1988;11:75–81.
17. Crum BA, Strommen JA. Peripheral nerve stimulation and monitoring during operative procedures. Muscle Nerve 2007;35:159–170.
18. Omejec G, Podnar S. What causes ulnar neuropathy at the elbow? Clin Neurophysiol 2016;127:919–924.
19. Grundfest H. Effects of hydrostatic pressures upon the excitability, the recovery, and the potential sequence of frog nerve. Cold Spring Harb Symp Quant Biol 1936;4:179–187.
20. Dyck PJ, Dyck JB, Engelstad J. Pathologic alterations of nerves. In: Dyck PJ, Thomas PK, editors. Peripheral neuropathy, 4th ed. Philadelphia: Saunders; 2005. p 733-829.
21. Kimura J. The carpal tunnel syndrome: localization of conduction abnormalities within the distal segment of the median nerve. Brain 1979;102:619–635.